Check for updates

Received: 9 July 2020 | Revised: 7 December 2020 | Accepted: 10 January 2021

DOI: 10.1111/jfbc.13628

FULL ARTICLE

Journal of Food Biochemistry WILEY

Ameliorative effect of umbelliferone in remote organ injury induced by renal ischemia-reperfusion in rats

Feyza Icoglu Aksakal[1] | Kubra Koc[2] | Fatime Geyikoglu[2] | Songul Karakaya[3]

[1]Department of Agricultural Biotechnology, Faculty of Agriculture, Ataturk University, Erzurum, Turkey

[2]Department of Biology, Faculty of Science, Atatürk University, Erzurum, Turkey

[3]Department of Pharmacognosy, Faculty of Pharmaceutical Botany, Atatürk University, Erzurum, Turkey

Correspondence
Kubra Koc, Department of Biology, Faculty of Science, Atatürk University, Erzurum 25240, Turkey.
Email: kubrakc@hotmail.com

Abstract

We evaluated the ameliorative role of umbelliferone in kidney, heart, and lung damage induced by renal ischemia/reperfusion (I/R) injury in rats. Umbelliferone was given orally to rats 60 min before ischemia. Ischemia was induced for 50 min and then reperfusion for 3 hr. The antioxidant enzymes, myeloperoxidase (MPO) activity, malondialdehyde (MDA) content, and cytokine levels in the kidney, heart, and lung were measured by ELISA. Moreover, histopathological changes were monitored. Renal I/R-induced oxidative stress in the organs by decreasing antioxidant enzymes. However, umbelliferone pretreatment enhanced superoxide dismutase (SOD) and glutathione (GSH), levels, reduced MDA and MPO levels. Renal I/R increased in tumor necrosis factor-alpha (TNF-α), interleukin-6 (IL-6) levels, and histopathological changes but these effects were inhibited with umbelliferone pretreatment. Furthermore, umbelliferone increased in nitric oxide synthase (eNOS) level under ischemia conditions. Our results indicated that pretreatment of umbelliferone-ameliorated damages in remote organ induced by renal I/R through suppressing oxidative stress and modulating inflammatory responses.

Practical applications

kidney, heart, and lung damages induced by renal I/R in rats was alleviated by umbelliferone. The oral treatment of umbelliferone markedly reversed the oxidative stress, inflammation, and histopathological changes by increasing in the levels of SOD, GSH, and eNOS, decreasing in the levels of MDA, MPO, TNF-α, and IL-6 in distant organ injury induced by renal I/R. This study firstly revealed that umbelliferone has potent antioxidant and anti-inflammatory activity in the remote organ damages caused by renal I/R. Consequently, umbelliferone may be an alternative therapeutic agent for treating renal I/R-induced damages.

KEYWORDS

antioxidant enzymes, cytokines, renal ischemia/reperfusion, umbelliferone

1 | INTRODUCTION

Renal ischemia-reperfusion (I/R) injury is one of the common causes of acute kidney injury observed in the majority of patients treated in intensive care units (Amini et al., 2019; Liu et al., 2018; Yap & Lee, 2012; Youssef et al., 2015). Although most of these patients receive renal plasma treatment, the treatment is often insufficient to protect patients from the high risk of death. Renal I/R damage causes multiple organ dysfunctions and a high risk of death, usually occurs as a result of this condition (Dépret et al., 2017; Elshazly

 © 2021 Wiley Periodicals LLC.

& Soliman, 2019; Shih et al., 2018; Yap & Lee, 2012). In the renal I/R damage, the amount of reactive oxygen species (ROS) and cytokine levels increase, leading to excessive inflammatory responses (Kalogeris et al., 2012; Mitaka et al., 2014; Zhao et al., 2018). ROS has an important role in cell damage caused by renal I/R. The imbalance between ROS production and elimination leads to an increase in oxidative stress. An increasing number of studies have revealed that renal I/R is related to decreased levels of enzymatic and nonenzymatic antioxidants, and accumulation of intracellular ROS (Elshazly & Soliman, 2019; Karim et al., 2015; Wang et al., 2010). Renal I/R injury causes damage to remote organs such as the lung, heart, and liver (Dépret et al., 2017; Yap & Lee, 2012). For example, Gu et al. (2011) demonstrated that a-45 min renal ischemia followed by 6 hr of reperfusion induced significant pulmonary injuries and enhanced MPO activity in rats. Ologunde et al. (2014) reported that renal I/R caused an increase in vascular permeability, T-lymphocyte infiltration, and neutrophil amount in the liver. Liu et al. (2008) and Grams and Rabb (2012) showed that renal I/R lead to an augmentation of vascular permeability in brain, increased cerebral pro-inflammatory cytokines disruption in the blood brain barrier, and microgliosis. Mitaka et al. (2014) reported that renal I/R significantly enhanced cytokine levels in the heart. Although some antioxidant and anti-inflammatory treatments are used to reduce renal I/R-induced injury (Gandhi et al., 2009; Liakopoulos et al., 2019), these applications do not reduce the mortality rates of critically ill patients in the intensive care units (Liu et al., 2018; Yang et al., 2017; Youssef et al., 2015). Therefore, new and effective therapies are required to prevent and reduce distant organ damages induced by renal I/R injury.

Coumarins are generally found in members of the Umbelliferae and Rutaceae families and constitute an important group of phenolic compounds (Hassanein et al., 2018). This group of phenolic substances is also known as natural products having various pharmacological activities with low toxicity to humans. Umbelliferone is a yellowish-white, crystalline, and ethanol-soluble bioactive molecule that is naturally found in plants such as golden apple and *Ferulago* genus and is considered the main active component of complex coumarins (Ramesh & Pugalendi, 2006; Vasconcelos et al., 2009). This molecule has pharmacological activities such as antioxidant, anti-inflammatory, antibacterial, antidiabetic, and antitumor (Anwar et al., 2015; Garud & Kulkarni, 2017; Mahmoud et al., 2019). Previous studies have shown that umbelliferone possesses ameliorative effects against myocardial infarction induced by isoproterenol, hepatotoxicity induced by N-nitrosodiethylamine, liver fibrosis induced by CCl4, myocardial injury induced by ischemia-reperfusion, and inflammatory responses induced by Lipopolysaccharide (Jagadeesh et al., 2016; Mahmoud et al., 2019; Subramaniam & Ellis, 2016; Wang et al., 2019). Besides, it has been shown that umbelliferone reduced liver injury in diabetic mice by suppressing the inflammatory response and alleviated the inflammatory response induced by cerebral I/R injury (Wang et al., 2015; Yin et al., 2018).

However, the effect of umbelliferone on distant organ injury induced by renal I/R is unknown. Hence, this study aims to evaluate whether distant organ injury induced by renal I/R can be amelioration with the administration of umbelliferone in rats. The remote organ injury was determined in kidney, heart, and lung tissues via oxidative stress, antioxidant enzyme activity as well as inflammatory cytokines levels.

2 | MATERIAL AND METHODS

2.1 | Umbelliferone

Umbelliferone was isolated from *Ferulago cassia* Boiss. (Apiaceae) roots. *Ferulago cassia* is known as "şeytan kişnişi" in Turkey and is a glaucescent, glabrous, and perennial species. It grows in Konya and Adana, Southern Anatolia, Turkey. Detailed isolation protocol and chemical properties of umbelliferone, obtained from *Ferulago cassia*, have been given by the method of Karakaya, Koca, et al. (2019), Karakaya, Yilmaz-Oral, et al. (2019).

2.2 | NMR data of umbelliferone

NMR (^{1}H, ^{13}C, HMBC, HMQC, COSY, and TOCSY) experiments were performed at 400 MHz in a Varian Mercury. The chemical shifts were evaluated in deuterochloroform and expressed, and then, IR spectra were recorded on a Horiba FT-720 IR spectrometer utilizing a KBr disk. Umbelliferone was gained as a white solid powder; ^{1}H-NMR (CD_3OD, 400 MHz): δ = 6.11 (1H, d, J = 9.3 Hz, H-3), 7.75 (1H, d, J = 9.3 Hz, H-4), 7.40 (1H, d, J = 8.7 Hz, H-5), 6.70 (1H, d, J = 8.4 Hz, H-6), 6.65 (1H, s, H-8); ^{13}C-NMR (CD_3OD, 400 MHz): δ = 161.32 (C-2), 111.24 (C-3), 144.58 (C-4), 111.75 (C-4′), 129.27 (C-5), 113.26 (C-6), 160.89 (C-7), 102.11 (C-8), and 155.59 (C-8′). ESIMS m/z 163.18 $[M^{+}Na]^{+}$.

2.3 | Animals

Eighteen female Wistar rats (240–250 g) obtained from Medical Experimental Application and Research Center, Atatürk University were used in the current study. Animals were housed in cages (3/cage) and maintained at controlled laboratory conditions (12/12: light/dark, 23 ± 2°C, 60 ± 10% humidity). They were fed with a commercially prepared normal rat diet throughout the study. The animal care and experimental protocols were approved by the Experimental Animal Ethics Committee, Ataturk University (No. 194, 04.11.2019).

2.4 | Renal ischemia-reperfusion and experimental protocol

Animals were randomly divided into three experimental groups (n = 6 each). Group 1 (sham, rats received 1% CMC solution), group 2 (renal I/R injury), and group 3 (rats received orally umbelliferone 100 mg/kg at 1 hr before renal I/R). The dose of umbelliferone was

selected according to our preliminary experiments and the literature data (Vasconcelos et al., 2009).

Rats were placed on a warming pad and anesthetized with 1.5% sevoflurane. Body temperature was kept at 37 ± 1°C. An abdominal incision was done after disinfection. Renal pedicles were bilaterally clamped for 50 min with vascular clamps. Then, blood flow to the kidneys was re-established by the removal of the clamps. Rats were sacrificed at 3 hr after the reperfusion. Sham-operated animals were subjected to the same procedure, excluding the placement of the clamps. At the end of the experiment, the kidney, heart, and lung tissues were carefully collected and placed in liquid nitrogen, and stored at −80°C until used for oxidative stress and inflammation analysis. Also, some of the tissues were directly fixed with 10% of buffered formalin phosphate for histology assessment.

2.5 | Estimation of oxidative stress and inflammation

Homogenates of the kidney, heart, and lung tissues were prepared for detection of superoxide dismutase (SOD) and glutathione (GSH), malondialdehyde (MDA), and myeloperoxidase (MPO), tumor necrosis factor-alpha (TNF-α), interleukin-6 (IL-6), and endothelial nitric oxide synthase (eNOS) by enzyme-linked immunosorbent assay (ELISA) kits (SunRed Biotech Co., China). Before each test, 2 g of tissue was weighed and ground with the help of liquid nitrogen and homogenized into 1 ml of PBS (pH = 7.2–7.4). The homogenate was centrifuged and the 40 μl of supernatant was used in each test and measurements. All the test was done according to the manufacturer's instructions and calculations was performed by preparing a standard curve.

2.6 | Histopathological assessments

The kidney, heart, and lung tissues were fixed in 10% of formaldehyde solution for 24 hr. Later, the tissue samples were processed through increasing concentration of ethanol, three changes of xylene, and three changes of paraffin. The samples were embedded in paraffin, and then, serially sectioned (5-μm thick) using a Leica RM2135 microtome (Leica, Bensheim, Germany). Sections were deparaffinized in xylene, rehydrated through decreasing concentrations of ethanol, and washed in PBS for staining with hematoxylin and eosin (H&E). Sections were stained with hematoxylin (5 min), washed in water, and then, rinsed in 1% acid alcohol. After washed, sections were placed in 1% eosin (5 min), followed by rinsing in water, then, dehydrated and were mounted on glass slides. Analysis of the sections was performed by two independent pathologists blindly. The pathologists continuously observed at least 10 high-power fields (×200) for each slice. They examined from randomly selected kidney, heart, and lung tissue sections of six animals in each group.

2.7 | Statistical analysis

All data were presented as the mean ± *SEM*. GraphPad prism 5.0 statistics software was used for statistical analysis (GraphPad, La Jolla, CA, USA). One-way analysis of variance (ANOVA) was performed to determine differences among groups. $p < .05$ was considered as statistically significant.

3 | RESULTS

The protective effect of umbelliferone on the kidney, heart, and lung damage was evaluated by determining GSH, MDA, and MPO levels, SOD enzyme activity and some cytokines (TNF-α, IL-6, and eNOS) levels. As shown in Figure 1, compared to the sham groups, MDA and MPO levels were significantly increased by renal I/R ($p < .0001$), whereas administration of umbelliferone significantly reduced in these parameters in kidney ($p < .0001$), heart ($p < .0001$), and lung ($p < .0001$). Renal I/R also affected GSH levels and SOD activity in all tissues. Both GSH levels and SOD activity significantly inhibited under renal I/R conditions ($p < .0001$). On the contrary, pretreatment with umbelliferone remarkably increased GSH level and SOD activity compared to the renal I/R groups ($p < .0001$).

A statistically significant increase in TNF-α and IL-6 was noted in the kidney, heart, and lung tissues after the renal I/R ($p < .0001$). Umbelliferone pretreatment inhibited TNF-α and IL-6 levels compared to the I/R groups ($p < .0001$). On the contrary, a significant decrease in eNOS levels was observed in the renal I/R groups compared to the sham groups for all three organs ($p < .0001$). In contrast, umbelliferone pretreatment significantly elevated the levels of eNOS in the kidney and heart in comparison to the renal I/R groups ($p < .0001$). In the lung, umbelliferone did not lead to differences in the level of eNOS (Figure 2).

Histopathological changes in kidney, heart and lung tissues under I/R and umbelliferone pretreatment were given in Figure 3. As illustrated in Figure 3, histopathological analyses by H&E staining displayed normal histology of kidney, hearth, and lung tissues in sham group. The renal I/R caused severe hemorrhage, congestion, apoptosis, necrosis, tubular dilatation, and hyalinization in kidney tissue (Figure 3a–c), while umbelliferone pretreatment reduced these histopathological changes (Figure 3). Compared to the sham group, renal I/R induced a hearth injury characterized by remarkable congestion, hemorrhage, apoptosis, necrosis, and cell infiltration. However, umbelliferone pretreatment suppressed hearth injury and the number of histopathological changes. As shown in Figure 3, lung tissue in the sham group exhibited normal tissue morphology, while lung in the I/R group displayed neutrophil congestion and hemorrhage. However, umbelliferone pretreatment in the renal I/R group prevented the occurrence of congestion and hemorrhage.

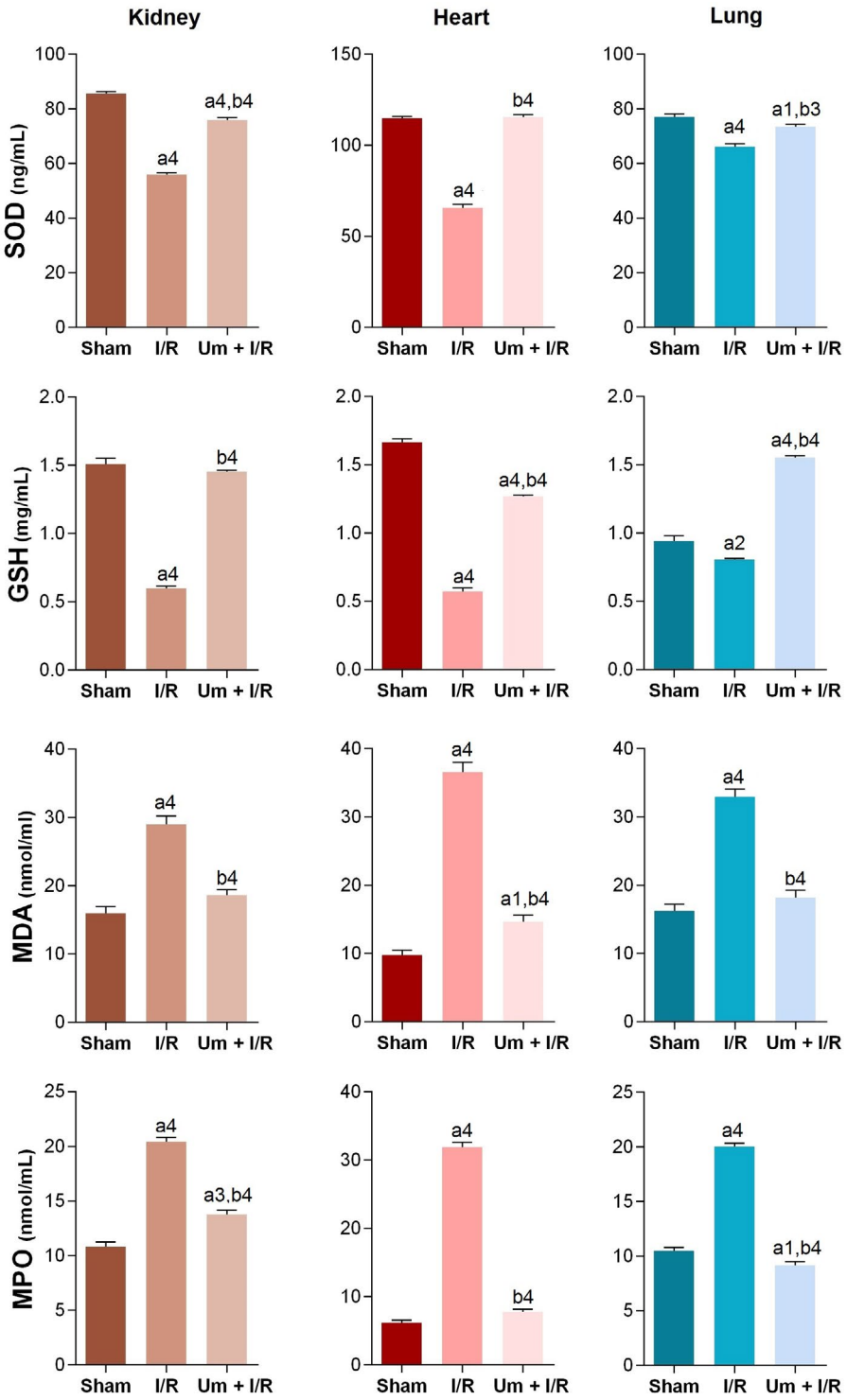

FIGURE 1 The effects of Umbelliferone on SOD, GSH, MDA, and MPO levels in rat kidney, heart, and lung after renal I/R. Data are presented as mean ± *SEM* ($n = 6$). "a" denotes significant differences between sham and other studied groups (a1: $p < .05$, a2: $p < .01$, a3: $p < .001$, a4: $p < .0001$), "b" denotes significant differences between Umbelliferone pretreatment group and I/R group (b3: $p < .001$, b4: $p < .0001$) by Tukey's multiple range tests. I/R, ischemia/reperfusion; Um, umbelliferone

4 | DISCUSSION

Remote organ damage is one of the most important causes of death in patients with acute renal injury induced by renal I/R. Renal I/R mostly affects vital organs such as the heart, liver, and lung. Previous studies have indicated that renal I/R led to excessive oxidative stress and increased inflammatory responses (Elshazly & Soliman, 2019; Kelly, 2003; Mitaka et al., 2014). On the contrary, a lot of researchers have shown that umbelliferone possesses multiple pharmacological effects, including anti-inflammatory, antimicrobial, and free radical scavenging activity (Garud & Kulkarni, 2017; Hassanein et al., 2018; Mahmoud et al., 2019; Ramesh & Pugalendi, 2006). Hence, in the

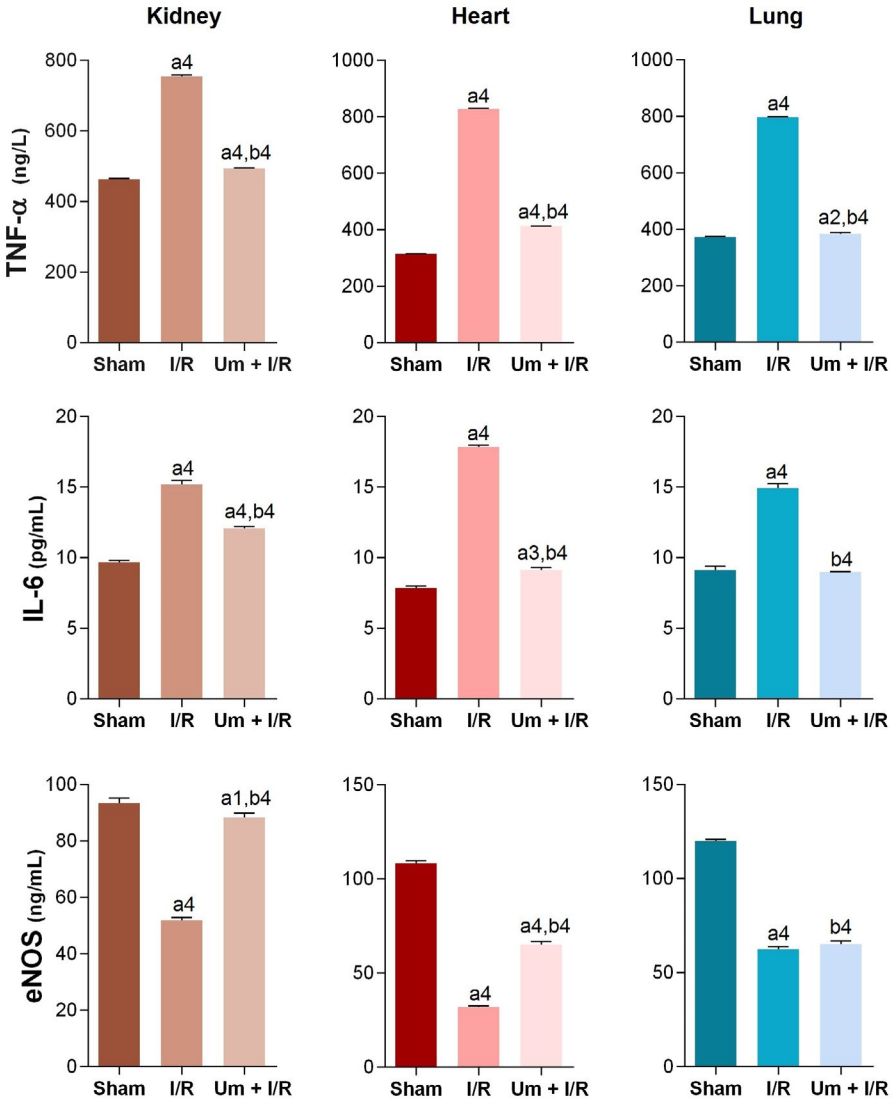

FIGURE 2 The effects of Umbelliferone on cytokine levels in rat kidney, heart, and lung after renal I/R. Data are presented as mean ± *SEM* ($n = 6$). "a" denotes significant differences between sham and other studied groups (a1: $p < .05$, a2: $p < .01$, a3: $p < .001$, a4: $p < .0001$), "b" denotes significant differences between Umbelliferone pretreatment group and I/R group (b4: $p < .0001$: $p < .0001$) by Tukey's multiple range tests. I/R, ischemia/reperfusion; Um, umbelliferone

present study, we evaluated the effects of renal I/R injury on remote organs, including heart and lung, and the protective effects of umbelliferone treatment before I/R injury by measuring some biochemical parameters in rats.

In the present study, renal I/R decreased GSH, eNOS levels, and SOD activity and increased MDA and MPO levels in all the studied organs. These results are consistent with previous studies demonstrating that renal I/R is associated with oxidative stress in remote organs such as the lung and heart. For example, Youssef et al. (2015) reported that renal I/R enhanced MDA levels in kidney and heart, and inhibited SOD and GSH levels. Yener et al. (2015) stated that lung GSH and SOD activities decreased, while MDA levels increased after renal I/R injury. ROS have been known to have an important role in initiating oxidative stress during I/R process (Walker et al., 2001). ROS oxidizes the lipids to generate peroxides and aldehydes, resulting in cell membrane lipid peroxidation (LPO). LPO products (MDA) can extend the responses and injury initiated by ROS in ischemia-reperfusion. They are detoxified by enzymatic and nonenzymatic antioxidants such as SOD and GSH (Ighodaro & Akinloye, 2018). In this study, umbelliferone pretreatment inhibited increased MDA and MPO in kidney, heart, and lung after renal I/R. MPO is used as an indicator of the accumulation of neutrophils in ischemia-reperfusion conditions in kidney (Chatterjee et al., 2005). This demonstrates that administration of umbelliferone could suppress neutrophil augmentation and oxidative stress in remote organs. Besides, GSH levels and SOD activity suppressed by I/R increased by pretreatment of umbelliferone. Together, these results suggested that the protective effects of umbelliferone against renal I/R-induced remote organ damages may be connected with the antioxidant effects of this coumarin. In consistent with our results, Gan et al. (2018) found that umbelliferone enhances SOD activity and inhibits the level of myocardial ischemia-induced MDA.

Previous studies have reported that excessive oxidative stress stimulated the overproduction of characteristics inflammatory

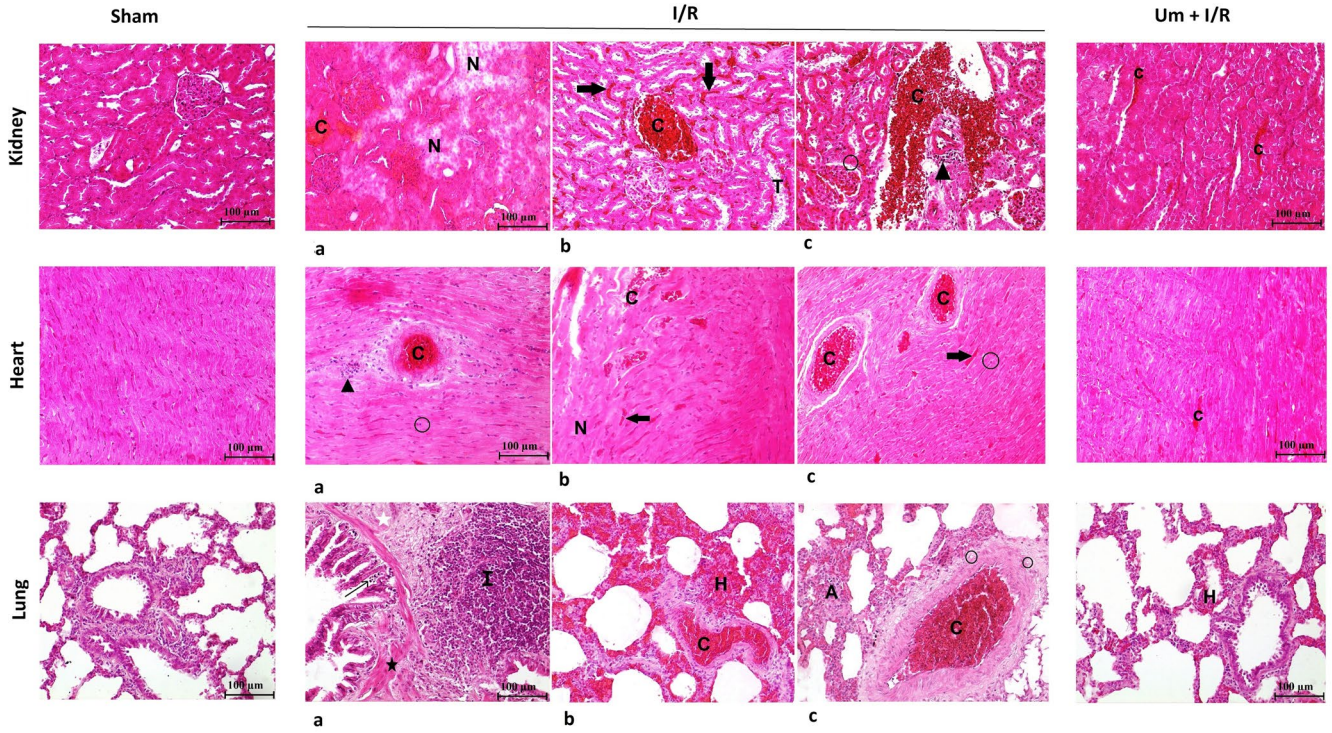

FIGURE 3 Histopathological changes of kidney, heart, and lung tissues after I/R procedure. Sham kidney; normal structure of kidney, I/R kidney; (a) C: congestion, N: necrosis. (b) C: congestion, T: tubular dilatation, Thick arrow: hemorrhage. (c) C: congestion, Arrow heads: infiltration, Circle: apoptosis. Um + I/R kidney; decreased congestion. C: congestion. Sham heart; normal structure of heart, I/R heart; (a) C: congestion, Arrow heads: infiltration, Circle: apoptosis. (b) C: congestion, N: necrosis, Thick arrow: hemorrhage. (c) C: congestion, Thick arrow: hemorrhage, Circle: apoptosis. Um + I/R heart; decreased congestion. C: congestion. Sham lung; normal structure of pulmonary, I/R lung; (a) I: infiltration, Thin arrow: epithelial cell spills, Black asterisk: increased fibrous tissue, White asterisk: smooth muscle hypertrophy. (b) C: congestion, H: hemorrhage. (c) A: thickening of the alveolar septa, C: congestion, Circle: vacuolization. Um + I/R lung; H: hemorrhage. I/R, ischemia/reperfusion; Um, umbelliferone

cytokines, including IL-6 and TNF-α (Geyikoglu et al., 2019; Mitaka et al., 2014; Oguz et al., 2015). TNF-α is one of the most important pro-inflammatory cytokines that induce the production of adhesion molecules in endothelial cells and leukocyte in various disease conditions. TNF-α also induces other inflammatory cytokines including IL-6 (Godet et al., 2006). Inflammatory response plays a vital role in renal I/R injury. Under I/R injury, cytokine expression is a transient response triggered by the activation of various pro-inflammatory cells. In this study, renal I/R markedly enhanced the levels of IL-6 and TNF-α relative to that of the sham group in the kidney, heart, and lung. On the contrary, umbelliferone pretreatment inhibited the increase of IL-6 and TNF-α caused by renal I/R. It is well known that umbelliferone has strong anti-inflammatory properties. The ability of umbelliferone to suppress the increment of pro-inflammatory cytokines such as IL-6 and TNF-α shows a significant anti-inflammatory effect on the kidney, heart, and lung. Similarly, Gan et al. (2018) reported that umbelliferone alleviated myocardial (MI) ischemia via reducing IL-6 and TNF-α levels. In parallel, Luo et al. (2018) showed that umbelliferone significantly inhibited IL-6 and TNF-α levels in MI/rats. Besides, Wang et al. (2019) have recently shown that administration of umbelliferone reduced the levels of IL-6 and TNF-α and displayed potent anti-inflammatory activity in diabetic nephropathy rats.

In our histopathological evaluation, serious structural defects were observed in the kidney, heart, and lung consistent with oxidative stress and inflammation after renal I/R. Previous studies have been reported that increased the levels of TNF-α and IL-6 after renal I/R play key roles in inducing the acute phase response and injury to distal organs including the heart and lungs by promoting an injurious inflammatory response (Donnahoo et al., 1999; Kelly, 2003; Kielar et al., 2005; Nechemia-Arbely et al., 2008). Besides, it was shown that high levels of TNF-α and IL-6 in circulating system increase histologic lesions in heart and lung (Royall et al., 1989). On the contrary, Kelly (2003) reported that TNF-a inhibition is associated with a decrease in cardiomyocyte apoptosis. Klein et al. (2008) observed that a decrease in the level of IL-6 after renal ischemia reperfusion prevents the formation of pulmonary injury in mice. In this study, in rats receiving umbelliferone developed less pulmonary and myocardial tissue damages, suggesting a protective role of umbelliferone in remote pulmonary and cardiac effect after renal I/R.

5 | CONCLUSION

We have observed that inflammation and oxidative stress play an important role in the pathophysiology of renal I/R-induced remote organ damages. We also found that oral treatment of umbelliferone markedly reduced oxidative stress, histopathological changes, and

inflammatory cytokines in remote organ injury caused by renal I/R. This study firstly revealed that umbelliferone has potent antioxidant and anti-inflammatory activity in renal I/R-induced remote organ damages. Consequently, umbelliferone may be an alternative therapeutic agent for treating renal I/R-induced damages, but further molecular studies are needed.

COMPLIANCE WITH ETHICAL STANDARDS

All animal experiments were performed following the standards denoted by Atatürk University Local Ethics Committee for Animal Experiments, No: 194, 04.11.2019.

CONFLICT OF INTEREST

All other authors declare that they have no conflict of interest.

AUTHOR CONTRIBUTION

FIA, contributed data acquisition, and wrote the paper. FG, designed the study and interpreted the data. KK, performed the experiments, analyzed, drafted, and revised the work. SK, obtained the umbelliferone. All authors read and approved the manuscript.

DATA AVAILABILITY STATEMENT

Data openly available in a public repository that issues datasets with DOIs.

ORCID

Kubra Koc https://orcid.org/0000-0001-6208-165X
Fatime Geyikoglu https://orcid.org/0000-0003-2488-1757

REFERENCES

Amini, N., Sarkaki, A., Dianat, M., Mard, S. A., Ahangarpour, A., & Badavi, M. (2019). Protective effects of naringin and trimetazidine on remote effect of acute renal injury on oxidative stress and myocardial injury through Nrf-2 regulation. *Pharmacological Reports*, *71*(6), 1059–1066. https://doi.org/10.1016/j.pharep.2019.06.007

Anwar, F., Al-Abbasi, F. A., Bhatt, P. C., Ahmad, A., Sethi, N., & Kumar, V. (2015). Umbelliferone β-d-galactopyranoside inhibits chemically induced renal carcinogenesis via alteration of oxidative stress, hyperproliferation and inflammation: Possible role of NF-κB. *Toxicology Research*, *4*(5), 1308–1323.

Chatterjee, P. K., Todorovic, Z., Sivarajah, A., Mota-Filipe, H., Brown, P. A. J., Stewart, K. N., Mazzon, E., Cuzzocrea, S., & Thiemermann, C. (2005). Inhibitors of calpain activation (PD150606 and E-64) and renal ischemia-reperfusion injury. *Biochemical Pharmacology*, *69*(7), 1121–1131. https://doi.org/10.1016/j.bcp.2005.01.003

Dépret, F., Prud'homme, M., & Legrand, M. (2017). A role of remote organs effect in acute kidney injury outcome. *Nephron*, *137*(4), 273–276. https://doi.org/10.1159/000476077

Donnahoo, K. K., Meng, X., Ayala, A., Cain, M. P., Harken, A. H., & Meldrum, D. R. (1999). Early kidney TNF-α expression mediates neutrophil infiltration and injury after renal ischemia-reperfusion. *American Journal of Physiology-Regulatory, Integrative and Comparative Physiology*, *277*(3), R922–R929. https://doi.org/10.1152/ajpregu.1999.277.3.R922

Elshazly, S., & Soliman, E. (2019). PPAR gamma agonist, pioglitazone, rescues liver damage induced by renal ischemia/reperfusion injury. *Toxicology and Applied Pharmacology*, *362*, 86–94. https://doi.org/10.1016/j.taap.2018.10.022

Gan, J., Qian, W., & Lin, S. (2018). Umbelliferone alleviates myocardial ischemia: The role of inflammation and apoptosis. *Inflammation*, *41*(2), 464–473. https://doi.org/10.1007/s10753-017-0702-6

Gandhi, C., Zalawadia, R., & Balaraman, R. (2009). Hesperidin improves warm ischemia/reperfusion-induced oxidative renal injury in rats. *Oriental Pharmacy and Experimental Medicine*, *9*(4), 292–302. https://doi.org/10.3742/OPEM.2009.9.4.292

Garud, M. S., & Kulkarni, Y. A. (2017). Attenuation of renal damage in type I diabetic rats by umbelliferone—A coumarin derivative. *Pharmacological Reports*, *69*(6), 1263–1269. https://doi.org/10.1016/j.pharep.2017.06.014

Geyikoglu, F., Koc, K., Colak, S., Erol, H. S., Cerig, S., Yardimci, B. K., Cakmak, O., Dortbudak, M. B., Eser, G., Aysin, F., Ozek, N. S., & Yildirim, S. (2019). Propolis and its combination with boric acid protect against ischemia/reperfusion-induced acute kidney injury by inhibiting oxidative stress, inflammation, DNA damage, and apoptosis in rats. *Biological Trace Element Research*, *192*(2), 214–221. https://doi.org/10.1007/s12011-019-1649-2

Godet, C., Goujon, J.-M., Petit, I., Lecron, J.-C., Hauet, T., Mauco, G., Carretier, M., & Robert, R. (2006). Endotoxin tolerance enhances interleukin-10 renal expression and decreases ischemia-reperfusion renal injury in rats. *Shock*, *25*(4), 384–388. https://doi.org/10.1097/01.shk.0000209528.35743.54

Grams, M. E., & Rabb, H. (2012). The distant organ effects of acute kidney injury. *Kidney International*, *81*(10), 942–948. https://doi.org/10.1038/ki.2011.241

Gu, J., Chen, J., Xia, P., Tao, G., Zhao, H., & Ma, D. (2011). Dexmedetomidine attenuates remote lung injury induced by renal ischemia-reperfusion in mice. *Acta Anaesthesiologica Scandinavica*, *55*(10), 1272–1278. https://doi.org/10.1111/j.1399-6576.2011.02526.x

Hassanein, E. H., Mohamed, W. R., Shalkami, A. G. S., Khalaf, M. M., & Hemeida, R. A. (2018). Renoprotective effects of umbelliferone on methotrexate-induced renal injury through regulation of Nrf-2/Keap-1, P38MAPK/NF-κB, and apoptosis signaling pathways. *Food and Chemical Toxicology*, *116*, 152–160. https://doi.org/10.1016/j.fct.2018.03.041

Ighodaro, O. M., & Akinloye, O. A. (2018). First line defence antioxidants-superoxide dismutase (SOD), catalase (CAT) and glutathione peroxidase (GPX): Their fundamental role in the entire antioxidant defence grid. *Alexandria Journal of Medicine*, *54*(4), 287–293. https://doi.org/10.1016/j.ajme.2017.09.001

Jagadeesh, G. S., Nagoor Meeran, M. F., & Selvaraj, P. (2016). Protective effects of 7-hydroxycoumarin on dyslipidemia and cardiac hypertrophy in isoproterenol-induced myocardial infarction in rats. *Journal of Biochemical and Molecular Toxicology*, *30*(3), 120–127. https://doi.org/10.1002/jbt.21770

Kalogeris, T., Baines, C. P., Krenz, M., & Korthuis, R. J. (2012). Cell biology of ischemia/reperfusion injury. *International review of cell and molecular biology*, *298*, 229–317.

Karakaya, S., Koca, M., Sytar, O., Dursunoglu, B., Ozbek, H., Duman, H., Guvenalp, Z., & Kılıc, C. S. (2019). Antioxidant and anticholinesterase potential of ferulago cassia with farther bio-guided isolation of active coumarin constituents. *South African Journal of Botany*, *121*, 536–542. https://doi.org/10.1016/j.sajb.2019.01.020

Karakaya, S., Yilmaz-Oral, D., Kilic, C. S., & Gur, S. (2019). Umbelliferone isolated from Zosima absinthifolia roots partially restored erectile dysfunction in streptozotocin-induced diabetic rats. *Medicinal Chemistry Research*, *28*(8), 1161–1167. https://doi.org/10.1007/s00044-019-02359-9

Karim, A. S., Reese, S. R., Wilson, N. A., Jacobson, L. M., Zhong, W., & Djamali, A. (2015). Nox2 is a mediator of ischemia reperfusion injury. *American Journal of Transplantation*, *15*(11), 2888–2899. https://doi.org/10.1111/ajt.13368

Kelly, K. J. (2003). Distant effects of experimental renal ischemia/reperfusion injury. *Journal of the American Society of Nephrology*, *14*(6), 1549–1558. https://doi.org/10.1097/01.ASN.0000064946.94590.46

Kielar, M. L., John, R., Bennett, M., Richardson, J. A., Shelton, J. M., Chen, L., Jeyarajah, D. R., Zhou, X. J., Zhou, H., Chiquett, B., Nagami, G. T., & Lu, C. Y. (2005). Maladaptive role of IL-6 in ischemic acute renal failure. *Journal of the American Society of Nephrology*, *16*(11), 3315–3325. https://doi.org/10.1681/ASN.2003090757

Klein, C. L., Hoke, T. S., Fang, W. F., Altmann, C. J., Douglas, I. S., & Faubel, S. (2008). Interleukin-6 mediates lung injury following ischemic acute kidney injury or bilateral nephrectomy. *Kidney International*, *74*(7), 901–909. https://doi.org/10.1038/ki.2008.314

Liakopoulos, V., Roumeliotis, S., Bozikas, A., Eleftheriadis, T., & Dounousi, E. (2019). Antioxidant supplementation in renal replacement therapy patients: Is there evidence? *Oxidative Medicine and Cellular Longevity*, *2019*, 1–23.

Liu, M., Liang, Y., Chigurupati, S., Lathia, J. D., Pletnikov, M., Sun, Z., Crow, M., Ross, C. A., Mattson, M. P., & Rabb, H. (2008). Acute kidney injury leads to inflammation and functional changes in the brain. *Journal of the American Society of Nephrology*, *19*(7), 1360–1370. https://doi.org/10.1681/ASN.2007080901

Liu, Z., Qu, M., Yu, L., Song, P., & Chang, Y. (2018). Artesunate inhibits renal ischemia-reperfusion-mediated remote lung inflammation through attenuating ROS-induced activation of NLRP3 inflammasome. *Inflammation*, *41*(4), 1546–1556. https://doi.org/10.1007/s10753-018-0801-z

Luo, H., Fan, Z., Xiang, D., Jiang, Z., Zhang, W., Gao, L., & Feng, C. (2018). The protective effect of umbelliferone ameliorates myocardial injury following ischemia-reperfusion in the rat through suppression NLRP3 inflammasome and upregulating the PPAR-γ. *Molecular Medicine Reports*, *17*(2), 3404–3410.

Mahmoud, A. M., Hozayen, W. G., Hasan, I. H., Shaban, E., & Bin-Jumah, M. (2019). Umbelliferone ameliorates CCl 4-induced liver fibrosis in rats by upregulating PPARγ and attenuating oxidative stress, inflammation, and TGF-β1/Smad3 signaling. *Inflammation*, *42*(3), 1103–1116. https://doi.org/10.1007/s10753-019-00973-8

Mitaka, C., Si, M. K. H., Tulafu, M., Yu, Q. I., Uchida, T., Abe, S., Kitagawa, M., Ikeda, S., Eishi, Y., & Tomita, M. (2014). Effects of atrial natriuretic peptide on inter-organ crosstalk among the kidney, lung, and heart in a rat model of renal ischemia-reperfusion injury. *Intensive Care Medicine Experimental*, *2*(1), 1–17. https://doi.org/10.1186/s40635-014-0028-8

Nechemia-Arbely, Y., Barkan, D., Pizov, G., Shriki, A., Rose-John, S., Galun, E., & Axelrod, J. H. (2008). IL-6/IL-6R axis plays a critical role in acute kidney injury. *Journal of the American Society of Nephrology*, *19*, 1106–1115. https://doi.org/10.1681/ASN.2007070744

Oguz, E., Yilmaz, Z., Ozbilge, H., Baba, F., Tabur, S., Yerer, M. B., & Hekimoglu, A. (2015). Effects of melatonin on the serum levels of pro-inflammatory cytokines and tissue injury after renal ischemia reperfusion in rats. *Renal Failure*, *37*(2), 318–322. https://doi.org/10.3109/0886022X.2014.991263

Ologunde, R., Zhao, H., Lu, K., & Ma, D. (2014). Organ cross talk and remote organ damage following acute kidney injury. *International Urology and Nephrology*, *46*(12), 2337–2345. https://doi.org/10.1007/s11255-014-0766-2

Ramesh, B., & Pugalendi, K. V. (2006). Antioxidant role of Umbelliferone in STZ-diabetic rats. *Life Sciences*, *79*(3), 306–310. https://doi.org/10.1016/j.lfs.2006.01.005

Royall, J. A., Berkow, R. L., Beckman, J. S., Cunningham, M. K., Matalon, S. A. D. I. S., & Freeman, B. A. (1989). Tumor necrosis factor and interleukin 1 alpha increase vascular endothelial permeability. *American Journal of Physiology-Lung Cellular and Molecular Physiology*, *257*(6), L399–L410. https://doi.org/10.1152/ajplung.1989.257.6.L399

Shih, J. M., Shih, Y. M., Hou, Y. C., Pai, M. H., Yeh, C. L., & Yeh, S. L. (2018). Effects of fish oil-based lipid emulsion on inflammation and kidney injury in mice subjected to unilateral hind limb ischemia/reperfusion. *Cytokine*, *111*, 49–57. https://doi.org/10.1016/j.cyto.2018.07.035

Subramaniam, S. R., & Ellis, E. M. (2016). Umbelliferone and esculetin protect against N-nitrosodiethylamine-induced hepatotoxicity in rats. *Cell Biology International*, *40*(7), 761–769. https://doi.org/10.1002/cbin.10611

Vasconcelos, J. F., Teixeira, M. M., Barbosa-Filho, J. M., Agra, M. F., Nunes, X. P., Giulietti, A. M., Ribeiro-dos-Santos, R., & Soares, M. B. P. (2009). Effects of umbelliferone in a murine model of allergic airway inflammation. *European Journal of Pharmacology*, *609*(1–3), 126–131. https://doi.org/10.1016/j.ejphar.2009.03.027

Walker, L. M., York, J. L., Imam, S. Z., Ali, S. F., Muldrew, K. L., & Mayeux, P. R. (2001). Oxidative stress and reactive nitrogen species generation during renal ischemia. *Toxicological Sciences*, *63*(1), 143–148. https://doi.org/10.1093/toxsci/63.1.143

Wang, B., Bai, M., Bai, Y., & Li, Q. (2010). Liver injury following renal ischemia reperfusion in rats. *Transplantation proceedings*, *42*, 3422–3426.

Wang, D., Wang, X., Tong, W., Cui, Y., Li, X., & Sun, H. (2019). Umbelliferone alleviates lipopolysaccharide-induced inflammatory responses in acute lung injury by down-regulating TLR4/MyD88/NF-κB signaling. *Inflammation*, *42*(2), 440–448. https://doi.org/10.1007/s10753-018-00953-4

Wang, X., Li, R., Wang, X., Fu, Q., & Ma, S. (2015). Umbelliferone ameliorates cerebral ischemia–reperfusion injury via upregulating the PPAR gamma expression and suppressing TXNIP/NLRP3 inflammasome. *Neuroscience Letters*, *600*, 182–187. https://doi.org/10.1016/j.neulet.2015.06.016

Yang, T., Zhang, X.-M., Tarnawski, L., Peleli, M., Zhuge, Z., Terrando, N., Harris, R. A., Olofsson, P. S., Larsson, E., Persson, A. E. G., Lundberg, J. O., Weitzberg, E., & Carlstrom, M. (2017). Dietary nitrate attenuates renal ischemia-reperfusion injuries by modulation of immune responses and reduction of oxidative stress. *Redox Biology*, *13*, 320–330. https://doi.org/10.1016/j.redox.2017.06.002

Yap, S. C., Lee, H. T., & Warner, D. S. (2012). Acute kidney injury and extrarenal organ dysfunction new concepts and experimental evidence. *Anesthesiology: The Journal of the American Society of Anesthesiologists*, *116*(5), 1139–1148. https://doi.org/10.1097/ALN.0b013e31824f951b

Yener, A. U., Sehitoglu, M. H., Ozkan, M. T., Bekler, A., Ekin, A., Cokkalender, O., & Kurt, T. (2015). Effects of kefir on ischemia-reperfusion injury. *European Review for Medical and Pharmacological Sciences*, *19*(5), 887–896.

Yin, J., Wang, H., & Lu, G. (2018). Umbelliferone alleviates hepatic injury in diabetic db/db mice via inhibiting inflammatory response and activating Nrf2-mediated antioxidant. *Bioscience Reports*, *38*(4). https://doi.org/10.1042/BSR20180444

Youssef, M. I., Mahmoud, A. A., & Abdelghany, R. H. (2015). A new combination of sitagliptin and furosemide protects against remote myocardial injury induced by renal ischemia/reperfusion in rats. *Biochemical Pharmacology*, *96*(1), 20–29. https://doi.org/10.1016/j.bcp.2015.04.010

Zhao, H., Huang, H., Alam, A., Chen, Q., Suen, K. C., Cui, J., Sun, Q., Ologunde, R., Zhang, W., Lian, Q., & Ma, D. (2018). VEGF mitigates histone-induced pyroptosis in the remote liver injury associated with renal allograft ischemia–reperfusion injury in rats. *American Journal of Transplantation*, *18*(8), 1890–1903. https://doi.org/10.1111/ajt.14699

How to cite this article: Icoglu Aksakal F, Koc K, Geyikoglu F, Karakaya S. Ameliorative effect of umbelliferone in remote organ injury induced by renal ischemia-reperfusion in rats. *J Food Biochem*. 2021;45:e13628. https://doi.org/10.1111/jfbc.13628