

Since January 2020 Elsevier has created a COVID-19 resource centre with free information in English and Mandarin on the novel coronavirus COVID-19. The COVID-19 resource centre is hosted on Elsevier Connect, the company's public news and information website.

Elsevier hereby grants permission to make all its COVID-19-related research that is available on the COVID-19 resource centre - including this research content - immediately available in PubMed Central and other publicly funded repositories, such as the WHO COVID database with rights for unrestricted research re-use and analyses in any form or by any means with acknowledgement of the original source. These permissions are granted for free by Elsevier for as long as the COVID-19 resource centre remains active.

Left Ventricular Thrombus in a Patient Infected by COVID-19

Elif Gozgec, MD, Hayri Ogul, MD, and Handan Alay, MD

Department of Radiology, Ataturk University School of Medicine, Erzurum, Turkey; and Department of Infectious Diseases, Ataturk University School of Medicine, Erzurum, Turkey

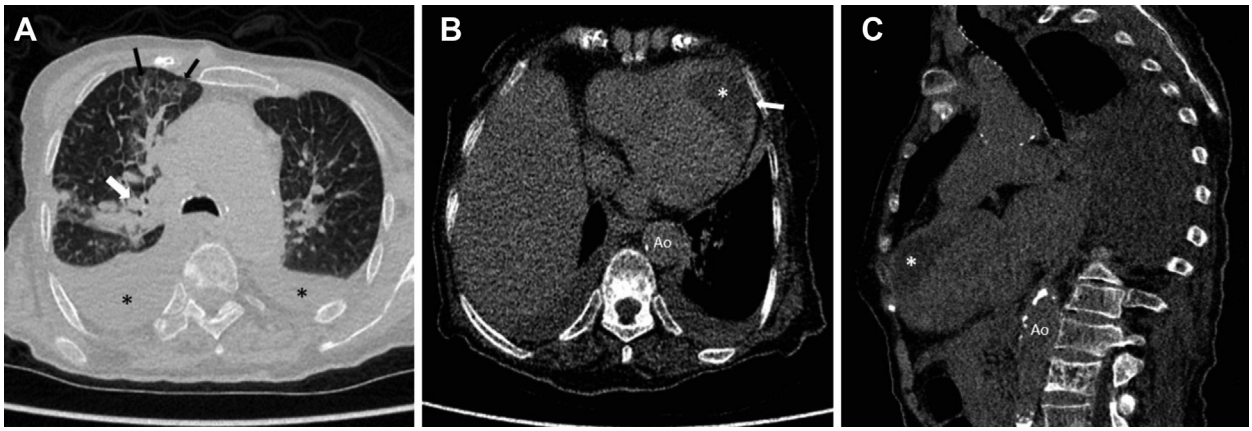

Figure 1.

A 74-year-old woman presented with generalized malaise with nausea and vomiting. The patient had no known systemic disease, history of trauma, or medication. On physical examination, the patient was confused and had abdominal tenderness. The chest roentgenogram showed cardiomegaly and bilateral pleural effusions. Computed tomography (CT) of the chest (Figure 1A) showed bilateral pleural effusions (black asterisks), consolidated areas with air bronchograms in the right hilar region (white arrow) and ground-glass densities in some peripheral locations (black arrows). In soft tissue window images (Figures 1B, 1C) abnormal enlargement of the left ventricular apex (white arrow) and a hypodense appearance (white asterisks) that could be compatible with thrombus were remarkable. On the basis of the present findings, the patient was given a diagnosis of multiple organ failure resulting from possible coronavirus disease 2019 (COVID-19). COVID-19 diagnosis of the patient could not be confirmed by test. She was intubated and taken to the intensive care unit. The patient became ex despite all efforts.

COVID-19, which has been declared a pandemic by the World Health Organization, has a variable clinical spectrum ranging from asymptomatic carriers to patients with multiple organ failure. Patients with COVID-19 have been shown to be susceptible to thrombus, which has frequently been found in the pulmonary arteries.[1,2] Ventricular thrombus, as in our case, is a very rare condition.

References

1. Marietta M, Ageno W, Artoni A, et al. COVID-19 and haemostasis: a position paper from Italian Society on Thrombosis and Haemostasis (SISET). *Blood Transfus*. 2020;18:167-169.
2. Wise J. Covid-19 and thrombosis: what do we know about the risks and treatment? *BMJ*. 2020;369:m2058.

Address correspondence to Dr Gozgec, Department of Radiology, The Hospital of Ataturk University, 25240, Erzurum, Turkey; email: elf.gvn@hotmail.com.

© 2021 by The Society of Thoracic Surgeons
Published by Elsevier Inc.

Ann Thorac Surg 2021;111:e67 • 0003-4975/$36.00
https://doi.org/10.1016/j.athoracsur.2020.07.008