Annals of Medical Research
DOI: 10.5455/annalsmedres.2019.09.516 2019;26(10):2376-81

Original Article

Are unresponsive dilated pupils an indicator for brain death? an evaluation of edinger westphal nucleus in rabbits with brain death

Ozgur Ozmen[1,4], Mehmet Aksoy[1,4], Canan Atalay[1,4], Mehmet Dumlu Aydin[2], Aysenur Dostbil[1,4], Ilker Ince[1,4], Ebru Sener[3]

[1]Ataturk University, Faculty of Medicine, Department of Anesthesiology and Reanimation, Erzurum, Turkey
[2]Ataturk University , Faculty of Medicine, Department of Neurosurgery, Erzurum, Turkey
[3]Ataturk University, Faculty of Medicine, Department of Pathology, Erzurum, Turkey
[4]Anesthesiology Clinical Research Office, Ataturk University, Erzurum, Turkey

Copyright © 2019 by authors and Annals of Medical Research Publishing Inc.

Abstract

Aim: To investigate a relationship between unresponsive pupils and severity of neurodegeneration in Edinger Westphal nucleus (EWN) of animals diagnosed with brain death.

Material and Methods: A total of 24 New Zealand white rabbits were used. The animals were divided into three groups, as control group (n=5), sham (n=5) and subarachnoid hemorrhage (SAH) group (n=14). Pupil diameters were measured after giving 2 mL of physiological saline for sham and 2 ml non-heparinized autologous arterial blood for the study group into the cisterna magna. Brain death was diagnosed in 10 rabbits in the SAH group. Then all animals were sacrificed. The brains, oculomotor nerves of all animals were extracted and stored in 10% formalin solutions for histopathological examination.

Results:TThe mean neuron numbers of Edinger Westphal nucleus was 253±43/mm3 in the control group; 244±12/mm3 in the sham group and 236±12/mm3 in dead unresponsive animals. Pupil diameters and degenerated neuron density of EWN in control, sham and SAH groups were found as follows, respectively: 8960±990µm-3±1/mm3; 10543±1.123µm-13±4/mm3 and 13540±1.356µm-63±11/mm3 (P<0.005). There was a positive relationship between degenerated neuron density of the EWN and pupil diameters (P<0.001). The mean nondegenerated neuron numbers were 170±32/mm3 in unresponsive pupils of examined animals.

Conclusion: In the absence of electrocardiographic/electroencephalographic functions, unresponsive pupils could not indicate real brain death.

Keywords: Brain death; unresponsive pupils; Edinger Westphal nucleus; degenerated neuron.

INTRODUCTION

A small hole in the center of the iris is named as pupil. Light enters the eye through the pupil and vision occurs. Two different smooth muscles (a circular group called the sphincter pupillae, and a radial group called the dilator pupillae) in the iris control the size of the pupil. While sphincter muscle is controlled by the parasympathetic nervous system, dilator sphincter muscle is controlled by the sympathetic nervous system. Photoreceptors, the cells in the retina respond to light and they send the impulse through axons in the optic nerve, optic chiasm, and optic tract. This impulse reaches the Edinger–Westphal nucleus (EWN) located in the rostral midbrain at the level of the superior colliculus. This nucleus is responsible for parasympathetic response originates. Both EWN receive identical afferent input and the impulse reaches to the pupilloconstrictor muscle via efferent nerve pathways including cranial nerve III. Thus, the consensual light reflex appears. Acetylcholine, a neurotransmitter is responsible for the synaptic response in pupillary constriction. On the other hand, sympathetic nervous system is responsible for pupil dilation. The sympathetic pathway originates in the posterior-lateral hypothalamus and it includes three neurons. The first neuron is ipsilateral preganglionic central neuron and it passes through the lateral brainstem to the

Received: 03.09.2019 **Accepted:** 16.10.2019 **Available online:** 22.10.2019
Corresponding Author: Mehmet Aksoy,Ataturk University, Faculty of Medicine, Department of Anesthesiology and Reanimation, Erzurum, Turkey, **E-mail:** drmaksoy@hotmail.com

spinal cord. The second preganglionic neuron synapses in the cervical ganglion. The third neuron is postganglionic neuron, it goes to the trigeminal ganglion, and it reaches the pupillodilator muscle in the iris. Norepinephrine is responsible for this synaptic reaction (1-3).

Various brain stem reflexes including corneal reflex, oculo cephalic reflex, oculovestibular reflex, cough reflex and gag reflexes are elicited in the diagnosis of brain death. Lesions of the upper brain stem or the third cranial nerve such as brain stem herniation, extensive intracranial pathology, haemorrhage, trauma, , diffuse brain injury, brain death and pharmacological blockade result in unilateral or bilateral fixed dilated pupils. The absence of the pupillary reflex to light is considered a criterion for brain death. Widely dilated pupils are not essential for brain death but fixed pupils with no response to light are mandatory (4-7).

Although unresponsive pupils have been accepted as important indicators of brain death, the degree of neuronal loss in EWN has not been seriously investigated in brain death determined animals. We hypothesised that nondegenerated neurons in EWN may be observed in individuals diagnosed with brain death and lost of function of the pupils may not be irreversible. Therefore, this experimental study was designed to investigate whether there was a relationship between unresponsive pupils and severity of neurodegeneration in EWN of animals diagnosed with brain death.

MATERIAL and METHODS

The Ethics Committee of Ataturk University, Erzurum, Turkey, approved experimental protocols. The study protocol was applied according to the the Guide for the Care and Use of Laboratory Animals (National Institutes of Health). In this present study, 24 New Zealand white rabbits were used. These rabbits were obtained from the Ataturk University Experimental Animal Laboratory. Prior to the start of the experiments, all rabbits were kept in the room with water and food ad libitum. Also, there are 12 h light/dark cycle, controlled temperature (22±1˚C) and humidity (50 70%) . To examine the brain death; light reflexes, pupillary answers to light, pupil diameters, EEG and ECG findings were recorded. Linear EEG and ECG was considered as brain and heart death. The pupil diameters of animals were measured in sunlight via ocular tomography before experiment. These results were saved as the baseline values. Three groups were formed, as control group (n=5), sham (n=5) and subarachnoid hemorrhage (SAH) group (n=14). The control group (n=5) were not subjected to any injections. They were used as for the normal,pathoanatomical and histopathological examinations of the oculomotor nerve cruising, Edinger Westphal nucleus. In the sham-operated group (n=5), 2 mL of saline was injected into the cisterna magna. In the SAH group (n=14), SAH model was established using a blood injection model (8). Anesthesia was maintained with a subcutaneous injection of 0.2 mL/kg of the anesthetic mixture (xylazine HCl, 30 mg/1.5 mL; ketamine HCl, 150 mg/1.5 mL and distilled water, 1 mL). Then isoflurane administered through a facemask before surgery. During the process, a dose of 0.1 mL/kg of the anesthetic mixture was used when required. In addition, injectable and balanced anesthetics were used to reduce pain and mortality. After vital signs were kept stable, a 22-gauge needle was inserted into the cisterna magna. When cerebrospinal fluid was observed from the needle, 2 ml non-heparinized fresh autologous auricular arteries blood was injected over the course of 1.5 min into the cisterna magna from the needle using aseptic technique and the injection lasted 1 minute. Pupil diameters were measured after giving 2 mL of physiological saline for sham and 2 ml non-heparinized autologous arterial blood for the study group into the cisterna magna. The animals were followed for 2-14 days without any medical treatment and their pupillary diameter measurements, ECGs and EEGs were recorded daily. Brain death was confirmed by the absence of brain stem reflexes, flatline electroencephalogram tracings, fixed dilated pupils, drop of mean arterial pressure and a positive apnea test. Brain death was diagnosed in 10 rabbits in the SAH group (9). Then all animals were sacrificed. The brain stems, oculomotor nerves and EWN of all animals were extracted. Tissues were stored in 10% formalin solutions and histopathological examination was done.

Pupillary light reflex measurements

Answers to pupillary light reflexes and the measurement of pupil diameters were performed on routine methods using Optical Coherence Tomography (RTVue-100, Optovue, Fremont, CA, USA) (10). Bilateral mydriatic unresponsive pupils to light were accepted as death criteria.

EEG-ECG wave recordings

Rats underwent cannulation of the tail artery for continuous blood pressure monitoring. Catheters were connected to the hemodynamic analysis system (Experimetria UK, London) and the mean blood pressure values were recorded. Three needle electrodes attached to the epidural regions of the scalp and electroencephalographic changes were recorded via an MP150 data acquisition system (BIOPAC systems, Inc. Goleta, CA, USA). In figure 1, normal, abnormal and linear form of EEG and ECG waves are seen in a rabbit. Linear EEG-ECG waves accepted as brain death criteria.

Anatomical examination

All pupils, brain stems, oculomotor nerves and EWN of all animals were examined gross anatomopathological characteristics.

Histopathological examination

All brains, brain stems, oculomotor nerves and Edinger-Westphal nuclei including brain areas were fixed in 10% formaline solution for five days. Then, all brain stems were horizontally sectioned at 2-mm distances from the origins of the oculomotor nerves, oculomotor nerve roots sections were embedded in paraffin blocks. To estimate the neuronal density of the Edinger–Westphal nuclei, the tissues were stained with H&E and GFAP and Tunnel

methods. The numbers of living and degenerated neurons in the EWN were identified using physical dissector and Cavalieri volume estimation methods (11). Multiplying the volume (mm3) by the numerical density was used to detect the total number of neurons in each specimen. The numbers of normal and degenerated neurons in the Edinger–Westphal nuclei of each animal were counted. The pupil diameter values were compared with the degenerated neuron densities of the EWN. Neurons were evaluated histologically (cellular darkening, cellular angulation, cytoplasmic condensation, nuclear shrinkage and neuronal degeneration).

All results were given as the mean±SD. The differences between the the pupil diameters and the numbers of degenerated neurons in the Edinger-Westphal nuclei were compared. A one-way ANOVA followed by Bonferroni post hoc test was used to detect the differences among the groups in terms of density of degenerated neurons in the Edinger Westphal nuclei, pupil diameter and physiological parameters. The P<0.05 was considered as significant.

RESULTS

Corneal reflex loss, pupillary enlargements, loss of light reflex or unresponsive pupils, linear configuration of EEG-ECG waves were recorded in brain death detected animals. Figure 1. shows pupil diameters and electrokardiographic parameters of rabbits in control (A), sham (B) SAH (C) groups. Documents of control, sham and SAH groups of all animals in terms of heart and respiratory rates as follows: 288±33/min-21±5/min; 226±31/min-15±4/min; 132±13/min-11±2/min. Pupil diameters in control, SHAM and SAH groups were found as follows, respectively: 8960±990µm; 10543±1.123µm and 13540±1.356µm (P<0.005). Figure 2 shows macroscopical appearances of a rabbit brain with OMN and section levels to examine EWN, histopathological section of OMNs at the brainstem and magnified form OMN fibers. Figure 3 shows anatomical appearances of OMN (Nııı) and section levels to examine EWN, Edinger Westphal nuclei center and magnified forms of degenerated Edinger Westphal neurons in a SAH created rabbit. Figure 4 shows histological appearances of OMN and interpeduncular cisterna filled with blood in SAH, bloody aquaduct and degenerated Edinger Westphal neurons with darkened cytoplasm, lessened volume and angularisation in a SAH created rabbit. Figure-5 shows histological appearances of EWN, normoform neurons and degenerated Edinger Westphal neurons with darkened cytoplasm, lessened volume and angularisation in a SAH created rabbit.

The mean neuron numbers of Edinger Westphal nucleus was 253±43/mm3 in the control group; 244±12/mm3 in the sham group and 236±12/mm3 in dead unresponsive animals. The degenerated neuron density of EWN in control, SHAM and SAH groups were found as follows, respectively: 3±1/mm3; 13±4/mm3 and 63±11/mm3 (P<0.005). There was a positive relationship between degenerated neuron numbers and pupil diameters in dead unresponsive animals. (p<0.001). The mean nondegenerated neuron numbers were 170±32/mm3 in unresponsive pupils detected animals.

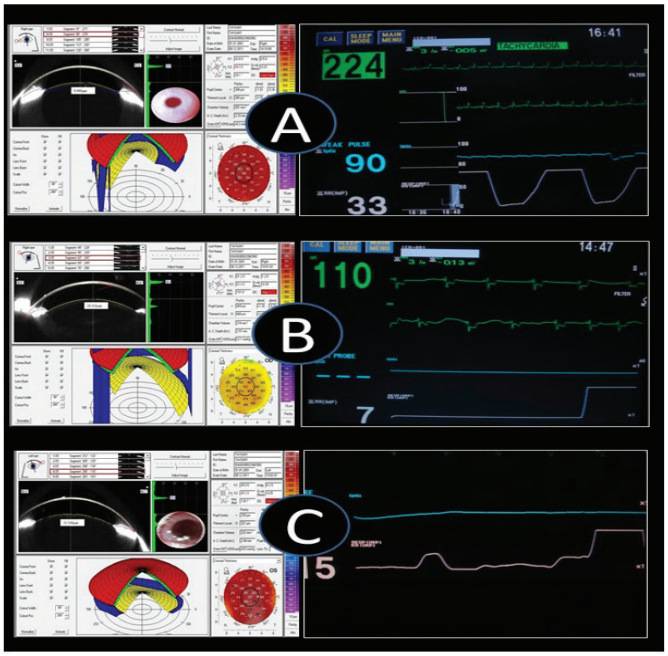

Figure 1. Pupil diameters and electrokardiographic parameters of rabbits in control (A), sham (B) and SAH (C) groups. Pupil diameter values were measured as 8960±990µm in control group; 10543±1.123µm in sham group and 13540±1.356µm in SAH group with the ocular tomography device (P<0.005).

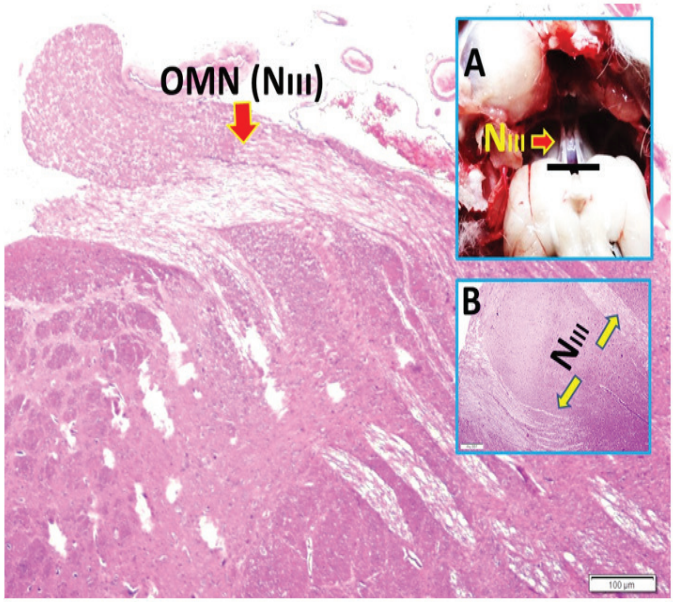

Figure 2. Macroscopical appearances of a rabbit brain with OMN and section levels to examine EWN (A), histopathological section of OMNs at the brainstem (LM,H&E,x4/B) and magnified form OMN fibers (LM,H&E,x10/Base).

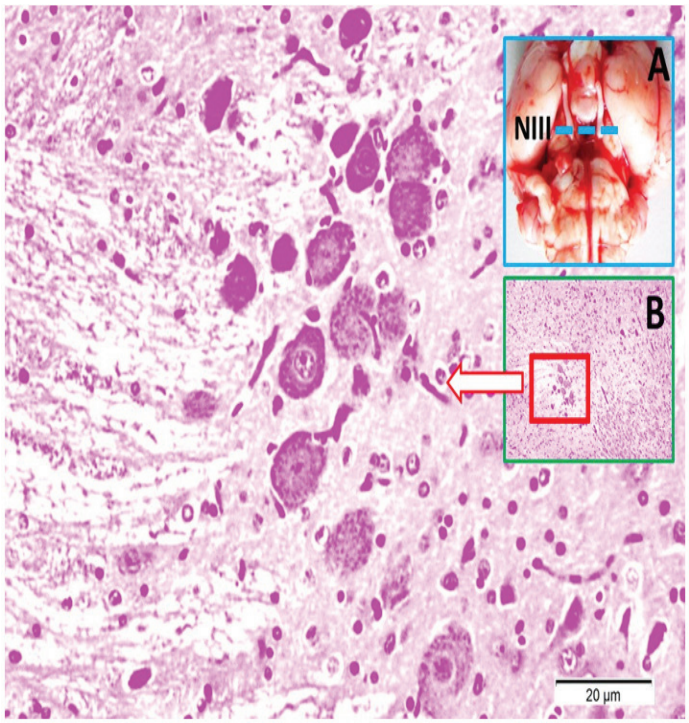

Figure 3. Anatomical appearances of OMN (NIII) and section levels to examine EWN (A), Edinger Westphal nuclei center (red square) (LM,H&E,x4/Base/B) and magnified forms of degenerated Edinger Westphal neurons (DN) (LM,HE,x20/Base) in a SAH created rabbit.

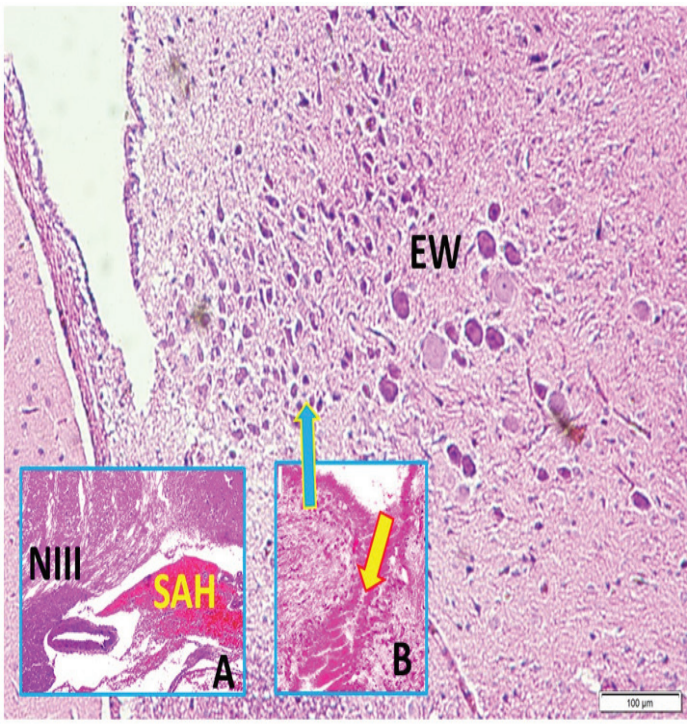

Figure 4. Histological appearances of OMN (NIII) and interpeduncular cisterna filled with blood in SAH (LM,H&E,x10/A), bloody aquaduct (LM,H&E,x10/B) and degenerated Edinger Westphal neurons with darkened cytoplasm, lessened volume and angularisation (LM,Tunel,x20/Base) in a SAH created rabbit.

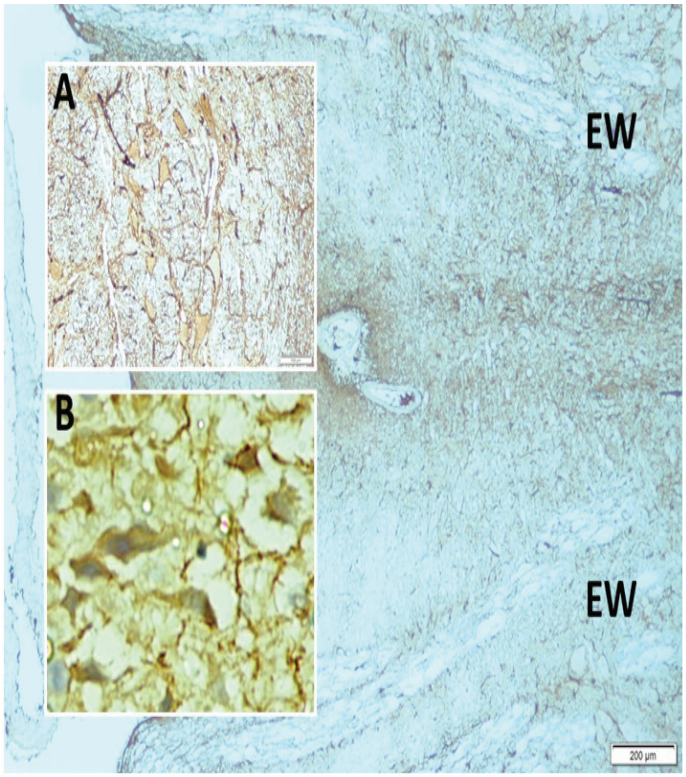

Figure 5. Histological appearances of EWN, normoform neurons (LM,GFAP,x10/A) and degenerated Edinger Westphal neurons with darkened cytoplasm, lessened volume and angularisation (LM,GFAP,x20/B) in a SAH created rabbit.

DISCUSSION

In this study, we investigated the relationship between unresponsive pupils and severity of neurodegeneration in Edinger Westphal nucleus in a rabbit diagnosed with brain death. We observed nondegenerated neurons in Edinger-Westphal nuclei in brain death and unresponsive pupils of inspected animals

The pupillary reflex is the reduction of pupil diameter in response to light. Normal response is dependent on the function of the photoreceptors, retinal nerve fibers, optic nerve, optic chiasm, rostral midbrain and oculomotor nerves. Parasympathetic effect is provided by Edinger-Westphal nuclei and it leads to pupillary constriction. On the other hand, hypothalamus is responsible for sympathetic effect and it provides pupillary dilation. Diseases disrupting communication in this system such as structural lesions in the hypothalamus or cervical spinal cord, metabolic disorders, drug intoxication lead to changes in pupil diameter. Lesions affecting the midbrain such as severe hypoxic-ischemic injuries disrupt both sympathetic and parasympathetic innervation. In this instance, symmetrically dilated pupils are observed (1-3). The selective loss of motor neurons in the oculomotor, facial and hypoglossal nuclei is observed in patients diagnosed with amyotrophic lateral sclerosis. In addition, these patients have a molecular dysfunction in the motor neurons of Edinger-Westphal nucleus (12). A neuronal loss in the Edinger-Westphal nucleus is evident in patients with

benign hereditary chorea (13). In the diagnosis of brain death and the evaluating prognosis in coma, pupillary reflex is important sign. Pupillodilator sympathetic and pupilloconstrictor parasympathetic reflexes regulate the pupil size. Mydriatic pupils may be observed in brain death and the sympathetic cervical spine pathways may be intact (3). Several authors suggested that mydriasis is not essential in patients diagnosed with brain death. Even, small or medium-sized pupils are found in brain death patients (14, 15). The pupillary examination is one of the few neurologic signs that doesn't require consciousness. In addition, it is a minimally invasive method providing valuable information about the status of brainstem function. The pupillary examination should include the examination of pupillary shape, reactivity to light, diameter and equality of pupils. The normal size of the pupil is 2-5 mm (average 3.5 mm), normal pupil shape is round (2).

In 1968, the committee of the Harvard Medical School faculty defined the concept of brain death. They proposed guidelines for clinical determination of brain death. Brain death is identified as the complete loss of all functions without return of the brainstem and brain (16). The guidelines for diagnosis of brain death in adults were created by American Academy of Neurology in 1995 and updated in 2010. According these guidelines, diagnosis of brain death is made in the presence of comatose patient with no brainstem reflexes and spontaneous breathing (17, 18). All brainstem reflexes including pupillary response, ocular movements, corneal reflex, cough and gag reflexes are absent in brain-dead patients. There are different institutional protocols for brain death determination in the World. For example, the Brain Death Study Group sponsored by the Japanese Ministry of Health and Welfare proposed following criteria for brain death determination: Glasgow Coma Scale score of 3, coma without response to painful stimuli, totally absent brainstem reflexes, bilaterally fixed pupils (>4 mm in size), apnea (final $PaCO_2$ of >60 mmHg) and an isoelectric electroencephalogram for >30 min (19). All tests should be repeated 6 h later. Whereas, the criteria for brain death in the USA are required bilaterally fixed pupils (>4 mm in size) (20). On the other hand, only the absence of a light reflex is required for brain death determination in Australian and New Zealand Intensive Care Society and the German criteria (21, 22). It remains unknown that the pupil size is always >4 mm in all cases diagnosed with brain death. The present study demonstrated the nondegenerated neurons in Edinger-Westphal nucleus in rabbits with experimental brain death. These results suggested that pupillary reflexes could not indicate real brain death. A mechanism of action for nondegenerated neurons in Edinger-Westphal nucleus remains to be elucidated. However, more investigations researching the impact of these nondegenerated neurons in brain death are required.

The present study is the first to demonstrate the nondegenerated neurons in Edinger-Westphal nucleus in rabbits diagnosed with brain death. Although basic clinical importance of the unresponsive pupils have been accepted as important indicators of brain death; the neurodegenerative changes of Edinger westphal nuclei has not been seriously investigated in brain death determined animals.

CONCLUSION

This study shown that in the absence of electrocardiographic/electroencephalographic functions, unresponsive pupils could not indicate real brain death. Because nondegenerated neurons could be observed in Edinger-Westphal nucleus in brain death detected animals. However, the action mechanism of the nondegenerated neurons in Edinger-Westphal nucleus in case of brain death remains to be investigated. If histopathological criterias of brain death would be replaced by clinical criterias, new descriptions about brain death should be required in the future.

Competing interests: The authors declare that they have no competing interest.

Financial Disclosure: There are no financial supports

Ethical approval: Experimental protocols were approved by the Ethics Committee of Ataturk University, Erzurum, Turkey. (B.30.2.ATA.0.23.85-41)
Ozgur Ozmen ORCID: 0000-0003-2014-0468

Mehmet Aksoy ORCID: 0000-0003-0867-8660
Canan Atalay ORCID: 0000-0002-4859-4616
Mehmet Dumlu Aydın ORCID: 0000-0002-0383-9739
Aysenur Dostbil ORCID: 0000-0002-7167-901X
Ilker Ince ORCID: 0000-0003-1791-9884
Ebru Sener ORCID: 0000-0002-0632-3527

REFERENCES

1. McDougal DH, Gamlin PD. Autonomic control of the eye. Compr Physiol 2015;5:439-73.
2. Neuhuber W, Schrödl F. Autonomic control of the eye and the iris. Auton Neurosci 2011;165:67-79.
3. Gu Q. Neuromodulatory Transmitter Systems in the Cortex and Their Role in Cortical Plasticity. Neuroscience 2002;111:815–35.
4. Drake M, Bernard A, Hessel E. Brain Death. Surg Clin North Am 2017;97:1255-73.
5. Rizvi T, Batchala P, Mukherjee S. Brain death: diagnosis and imaging techniques. Semin Ultrasound CT MR 2018;39:515-29.
6. Nelson A, Lewis A. Determining Brain Death: Basic Approach and Controversial Issues. Am J Crit Care 2017;26:496-500.
7. Wijdicks EFM, Varelas PN, Gronseth GS, et al. Evidence-based guideline update: determining brain death in adults: report of the Quality Standards Subcommittee of the American Academy of Neurology. Neurology 2010;74:1911-8.
8. Onen MR, Yilmaz I, Ramazanoglu L, et al. Uncovering the Forgotten Effect of Superior Cervical Ganglia on Pupil Diameter in Subarachnoid Hemorrhage: An

Experimental Study. Turk Neurosurg 2018;28:48-55.
9. Benzel EC, Mashburn JP, Conrad S, et al. Apnea testing for the determination of brain death: a modified protocol. J Neurosurg 1992;76:1029–31.
10. Chao Tian, Wei Zhang, Aghapi Mordovanakis, et al. Noninvasive chorioretinal imaging in living rabbits using integrated photoacoustic microscopy and optical coherence tomography. Paulus Opt Express 2017;25:15947–55.
11. Yilmaz A, Gündoğdu C, Aydin MA, et al. Trigeminal ganglion neuron density and regulation of anterior choroid artery vasospasm: In a rabbit model of subarachnoid hemorrhage. Surg Neurol Int 2011;2:77.
12. Ferrucci M, Spalloni A, Bartalucci A, et al. A systematic study of brainstem motor nuclei in a mouse model of ALS, the effects of lithium. Neurobiol Dis 2010;37:370-83.
13. Yoshida Y, Nunomura J, Shimohata T, et al. Benign hereditary chorea 2: pathological findings in an autopsy case. Neuropathology 2012;32:557-65.
14. Zhang TX, Shi YJ, Sheng HQ, et al. Clinical diagnosis of 26 cases of brain death. Zhonghua Yi Xue Za Zhi 2004;84:93-6.
15. Ishiguro T, Tamagawa S, Ogawa H. Changes of pupil size in brain death patients. Seishin Shinkeigaku Zasshi 1992;94:864-73.
16. Beecher HK: A definition of irreversible coma. Report of the ad hoc committee of Harvard Medical School to examine the definition of brain death. JAMA 1968;205:337-40.
17. Wijdicks EFM. Determining brain death in adults. Neurology 1995;45:1003-11.
18. Wijdicks EFM, Varelas PN, Gronseth GS, et al. Evidence-based guideline update: determining brain death in adults: report of the Quality Standards Subcommittee of the American Academy of Neurology. Neurology 2010;74:1911-18.
19. Takeuchi K, Takeshita H, Takakura K, et al. Evolution of criteria for determination of brain death in Japan. Acta Neurochir (Wien) 1987;87:93-8.
20. Quality Standard Subcommittee of the American Academy of Neurology. Practice parameters: determining brain death in adults. Neurology 1995;45:1012–14.
21. Guignard NG, Gardner AI, Baker S, et al. Brain death determination in Australia and New Zealand: a survey of intensive care units. Crit Care Resusc 2011;13:271-3.
22. Thömke F, Weilemann LS. Current concepts in diagnosing brain death in Germany. Med Clin (Munich) 2000;95:85–9.