GENERAL SURGERY

Editor
Ömer ALABAZ

© Copyright 2021

Printing, broadcasting and sales rights of this book are reserved to Academician Bookstore House Inc. All or parts of this book may not be reproduced, printed or distributed by any means mechanical, electronic, photocopying, magnetic paper and/or other methods without prior written permission of the publisher. Tables, figures and graphics cannot be used for commercial purposes without permission. This book is sold with banderol of Republic of Turkey Ministry of Culture.

ISBN
978-625-7401-28-9

Name of Book
General Surgery

Editor
Ömer ALABAZ
ORCID iD: 0000-0001-5235-7392

Publishing Coordinator
Yasin DILMEN

Page and Cover Design
Typesetting and Cover Design by Akademisyen

Publisher Certificate Number
47518

Printing and Binding
Printing Press Vadi

Bisac Code
MED085000

DOI
10.37609/akya.173

WARNING

The information contained in this product is only presented as a source for licensed medical workers. It should not be used for any professional medical advice or medical diagnosis. It does not constitute a doctor-patient, therapist-patient and / or any other health-presentation service relationship between the Bookstore and the recipient in any way.

This product is not a synonym or a substitute for professional medical decisions. The Academician Bookstore and its affiliated companies, writers, participants, partners and sponsors are not responsible for injuries and / or damage to humans and devices arising from all applications based on product information.

In the case of prescription of drugs or other chemicals, checking over the current product information for each drug defined by the manufacturer to determine the recommended dose, duration, method and contraindications of the drug is recommended.

It is the physician's own responsibility to determine the optimal treatment an dose for the patient, and to establish a basis for the knowledge and experience of the treating physician about the patient.

The Academician Bookstore is not responsible for any changes to the product, repackaging and customizations made by a third party.

GENERAL DISTRIBUTION
Akademisyen Kitabevi A.Ş.

Halk Sokak 5 / A
Yenişehir / Ankara
Tel: 0312 431 16 33
siparis@akademisyen.com

www.akademisyen.com

PREFACE

Based in Ankara in Turkey, the independent academic publisher, Akademisyen Publishing House, has been publishing books for almost 30 years. As the directors of Akademisyen Publishing House, we are proud to publish around 1500 books across disciplines so far, especially in Health Sciences. We also publish books in Social Sciences, Educational Sciences, Physical Sciences, and also books on cultural and artistic topics.

Akademisyen Publishing House has recently commenced the process of publishing books in the international arena with the "Scientific Research Book" series in Turkish and English. The publication process of the books, which is expected to take place in March and September every year, will continue with thematic subtitles across disciplines

The books, which are considered as permanent documents of scientific and intellectual studies, are the witnesses of hundreds of years as an information recording platform. As Akademisyen Publishing House, we are strongly committed to working with a professional team. We understand the expectations of the authors, and we tailor our publishing services to meet their needs. We promise each author for the widest distribution of the books that we publish.

We thank all of the authors with whom we collaborated to publish their books across disciplines.

Akademisyen Publishing House Inc.

Contents

Chapter 1 Biliary Pancreatitis Diagnosıs and Treatment 1
Barış MANTOĞLU
Enis DİKİCİLER

Chapter 2 Current Evaluation of Acute Abdominal Pain 19
Burak DEMİRCİ

Chapter 3 Current Evaluation of Acute Pancreatitis 31
Çilem ÇALTILI

Chapter 4 Gallbladder Cancer 43
Emre GONULLU

Chapter 5 Minimal Invasive Approach in Pilonidal Sinus Treatment: Endoscopic Pilonidal Sinus Treatment 51
Rıfat PEKSÖZ
Esra DİŞÇİ
Enes AĞIRMAN

Chapter 6 Hiccup 59
Hüseyin Fatih SEZER

Chapter 7 Laparoscopic Surgery for Large Gallstones 65
Kenan BİNNETOĞLU
Serhat DOĞAN

Chapter 8 Anatomy Of Dorsalıs Pedıs Artery 71
Şeyma TOY
Erol TOY

Authors

Barış MANTOĞLU
Dr., Sakarya Üniversitesi Eğitim ve Araştırma Hastanesi Genel Cerrahi Bölümü.
ORCID iD: 0000-0002-2161-3629

Enis DİKİCİER
Dr. Öğr. Gör., Sakarya Üniversitesi Tıp Fakültesi Genel Cerrahi AD,
ORCID iD: EKSİK

Burak DEMİRCİ
Uzm. Dr., Sağlık Bilimleri Üniversitesi Bağcılar Eğitim ve Araştırma Hastanesi Acil Tıp Bölümü,
ORCID iD: 0000-0001-6658-7260

Çilem ÇALTILI
Uzm. Dr., Sağlık Bilimleri Üniversitesi Bağcılar Eğitim ve Araştırma Hastanesi Acil Tıp Bölümü,
ORCID iD: 0000-0001-8910-7004

Emre GONULLU
Sakarya University Research and Educational Hospital Department of General Surgery,
ORCID iD: 0000-0001-6391-4414

Rıfat PEKSÖZ
Assistant Professor, Ataturk University Faculty of Medicine,
ORCID iD: EKSİK

Esra DİŞÇİ
Assistant Professor, Ataturk University Faculty of Medicine,
ORCID iD: EKSİK

Enes AĞIRMAN
Research Assistant, Ataturk University Faculty of Medicine,
ORCID iD: 0000-0002-0289-1252

Hüseyin Fatih SEZER
Assistant Professor, Kocaeli University,
ORCID iD: 0000-0001-5812-7088

Kenan BİNNETOĞLU
Kafkas University, School of Medicine, Department of General Surgery,
ORCID iD: 0000-0001-7517-5970

Serhat DOĞAN
Malatya Traınıng And Research Hospıtal, Department of General Surgery,
ORCID iD: EKSİK

Şeyma TOY
M.D Erol TOY Karabük Training and Research Hospital, Department of Anesthesiology and Reanimation,
ORCID iD: 0000-0002-6067-0087

Erol TOY
Asst. Prof. Dr., Karabük University Faculty of Medicine,
ORCID iD: 0000-0001-6888-9924

Chapter 5

MINIMAL INVASIVE APPROACH IN PILONIDAL SINUS TREATMENT: ENDOSCOPIC PILONIDAL SINUS TREATMENT

Rıfat PEKSÖZ[1]
Esra DİŞÇİ[2]
Enes AĞIRMAN[3]

Pilonidal cyst disease is a chronic inflammatory process which is frequently developed on the sacrococcygeal area and is related with the existence of hair on that area [(1)]. This disease is seen approximately 3 times more often in men and is frequently seen in young people, especially in the third decade [(2)]. Some factors such as increase of hair on the disease area, male sex, inadequate hygiene, sedentary life and being overweight are accused for the formation of pilonidal sinus (PS) [(3,4)]. In addition to some patients who can be asymptomatic, pilonidal sinus can cause pain, recurrent abscess formation and acute or chronic infections [(5,6)]. Sacrococcygeal pilonidal disease was firstly described by Mayo in 1883 and since then, various treatment modalities have been improved for this disease's management [(6)].

Although several methods have been used over the years in PS treatment, any consensus cannot be generated on an ideal treatment [(7)]. The ideal treatment method should have some specific qualities for example; easily applicable, cost effective, small wound size, slight pain, rapid wound healing, simple wound care, return to daily activities as soon as possible, short term labor loss, low recurrence and complications [(3,8)].

Sacrococcygeal pilonidal disease's major treatment is surgery. Several treatment methods are defined in literature. These techiques are as follows; the excision of the sinus which is left open, excision and marsupialiastion, Karyadakis and Limberg like flap techniques with fibrin glue, thrombin-gelatine matrix or phenol injections with the curettage of the sinus [(6)]. The use of these minimal invasive techniques have been preferred more during the recent years for pilonidal sinus disease. In the minimal invasive surgery period, the use of endoscopy has

[1] Assistant Professor, Ataturk University Faculty of Medicine, rifat-peksoz@hotmail.com
[2] Assistant Professor, Ataturk University Faculty of Medicine, esradicsi16@gmail.com
[3] Research Assistant, Ataturk University Faculty of Medicine, agirman_enes@hotmail.com

taken part in PS disease in the context of increasing endoscopic methods [7]. In 2013, Meniore and his friends defined the Endoscopic Pilonidal Sinus Treatment (EPSIT) method which is known as a minimal invasive technique [9].

In this study; expression of EPSIT's surgery technique stages and its compression with other treatment methods in company with current literature is aimed.

E.P.S.I.T SURGERY TECHNIQUE STAGES

1: When the patient is in prone position, both gluteal areas are strapped with plaster and pulled throughout the lateral side.
2: After the operation area is cleaned, local anesthesia is applied to the sinus opening with 2% lidocaine. (On the other side, sedation can be applied.)
3: 0.5 cm circular incision is done to the outer opening of the sinus. With the help of a clamp, hair and debris are removed. (Figure 2)
4: The screen is arranged on the left side of the patient's head and the surgeon is positioned on right side of patient.
5: Meinero fistuloscope (Karl Storz™, Tuttlingen, Germany) is used to enter into the cyst which is then irrigated with Glycine/Mannitol 1 % solution or NaCl 0.9 %.
6: Hair and granulation tissue are removed with forceps and endobrush. (Figure 3)
7: Cauterization of the cyst cavity is done by monopolar. (Figure 4)
8: Crystalized phenol is injected into the cyst cavity and the operation is ended following medical dressing.

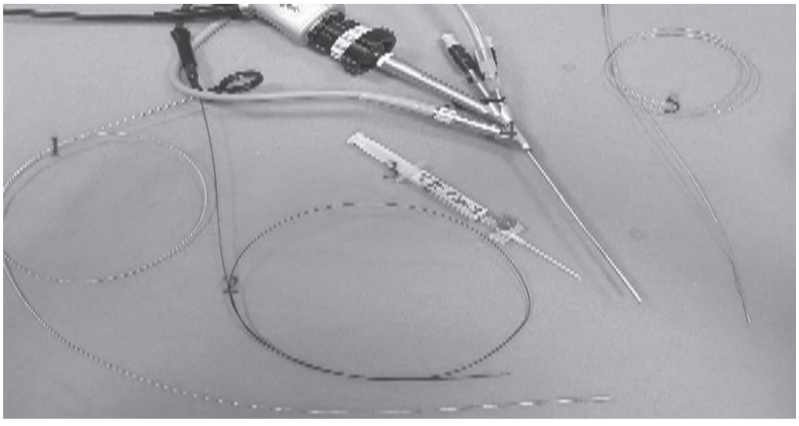

Figure 1: 1: Endobrush 2: Monopolar cautery 3: Phenol liquid 4: Cystoscope 5: Forceps (11)



Figure 2: Removal of hair and debris by clamp



Figure 3: Removal of remaining hair and debris by endobrush

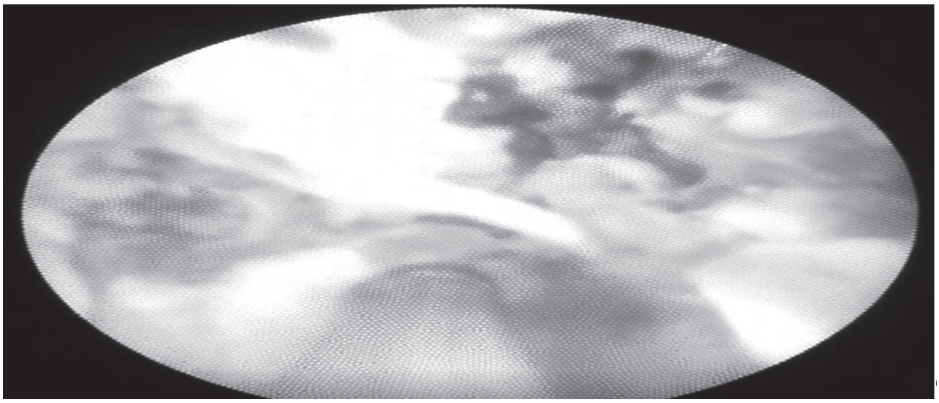

Figure 4: Cauterization of cyst cavity by monopolar

Patients are hospitalized on operation day and discharged from the hospital in the same day. There are different approaches in EPSİT applications. Instead of standard Meinero fistuloscope, cystoscope or hysteroscopy can also be used [10,11]. In certain studies, various materials can be injected into the sinus cyst, like phenol for example [11,12] (Figure 1).

POSTOPERATIVE MANAGEMENT

Preoperative IV ampicillin/sulbactam is applied. One day after the operation, the patient is discharged. Until the wound is closed, wound dressings should be performed with 10ml NaCl 0.9 %. Oral antibiotics (amoxicillin/clavulanic acid 2 × 1) and pain killers can be used for an entire week. Wound control postoperatively must be done in the first, second and third weeks [8].

DISCUSSION

EPSIT is a method that is constituted by being inspired from video-assisted anal fistula treatment (VAAFT) which is used in anal fistule operations [6]. EPSIT process includes the removal of infected parts while entering into the pilonidal sinus hole with a fistuloscope by an incision approximately 0,5 cm wide [3]. Several minimal invasive procedures are defined for PS disease. Although there are pilonidal sinus cavity curettages that are followed by minimal invasive techniques like phenol or fibrin glue local injections into the sinus, these methods are blind techniques and therefore hair and infected tissues cannot be totally removed from the inside of the sinus [13]. EPSIT allows surgeons to see the sinus tract and any secondary tract or cavity formation. Moreover; this technique directly allows the total removal of hair without removing any tissue and causing unnecessary damage [3]. Thus, EPSIT is a more effective method than other minimal invasive techniques.

After several surgical treatments in PS are applied, the recurrence rates changes between 0-40 % [13]. While this rate is 8 % for surgical excisions and primer closure [14], it is found to be 6 % for various flap procedures, 4.5 % in deroofing and curettage of the sinus technique [15] and 5.8 % for off-midline closure procedures [14]. While these techniques have decreasing recurrence rates, they cause high morbidities, long term hospitalizations and labor losses [3]. A meta-analytic study has shown that the recurrence rate after EPSIT is detected to be on average 6.3 %. Although the recurrence rates are similar to other methods, patients are very satisfied based on low postoperative pain, less incision area, rapid return to work and daily activities [6]. Compared to other minimal invasive processes, EPSIT has lower recurrence rates. This recurrence rate is 20 % in fibrin sealant injections [16] and is 13 % in phenol injections [17].

One of the most important criteria in the treatment of this disease is having a low complication rate. Some randomized studies show that complications of traditional methods like seroma, hematoma, deep infectious collection, wound separation and infection reach up to 25 % [18]. Limberg flap and Karydakis operations are the most commonly used asymmetric flap techniques. By comparison with median methods; the recurrence rates of these methods (8 %) are less; but infections and complications of the wound area are more common and wound healing is more difficult [8]. According to a recently done study in recurrent PS patients for deciding the effectiveness of Limberg and Karydakis flap, morbidity rates are detected as 53.5 % [19]. In a meta-analytic study which researches primer closure, rhomboidal excision and Limberg flap methods; the infection rate was seen as 9.24 %, the average hospitalization period was 5 days and total time to return to work was seen as 20 days [19]. Furthermore; in meta-analytic studies about EPSIT, average complication rates are reported as 1.6 % [6]. This rate is less than other methods and is within the acceptable level. Although EPSIT's complications are stated as 15.3 % in Peksöz and his friends' study, researchers say that this high level appears on the occasion of being new to the application of this method [11].

Nordon and Senapatinini's study stated that the time for returning to work after a Simple Bascom Procedure was two weeks [20]. After EPSIT, definite return to work was 3 days in average. This time difference is one of the most important advantages of this method which minimizes the economic loss due to the disease [6]. In a randomized study, EPSIT and conventional surgery (Bascomn cleft lift procedure) are compared. It is found out that EPSIT patients have higher satisfaction and require a shorter time to return work. However, a valid difference could not be shown in terms of complications and recurrence rates.

Even in recurrent sinus cases, the EPSIT method had satisfying results. In the study which was performed by Meinero and his friends, a 5.1% relapse rate and a 5% incomplete wound healing rate was found. Despite the fact that EPSIT has many advantages, it also has some limitations such as the cost of fistuloscope and its kit, and the training and experience required by the surgeons for this procedure.

RESULT

For pilonidal sinus disease, there is no definite treatment but minimal invasive procedures have started to be performed more frequently. In these methods, EPSIT is one of the best known. In primary sinus and recurrent sinus patients, EPSIT is an alternative procedure to flap technique and other ways of treatment. After surgery, getting back to work and one's own daily life is fast and disease related economical loss is decreased. EPSIT is a more effective procedure than traditional methods, in terms of having less complications, slighter pain, shorter hospitalization times, less incision scars, and an acceptable level of recurrence rates. Recently, endoscopic procedures have become the first choice for most of the surgeries. Thus, in the near future, it is thought that EPSIT may be a gold standard method of pilonidal sinus treatment.

REFERENCES

1. Bendewald, F.P., Cima, R.R. Pilonidal disease. *Clin Colon Rectal Surg. 2007;20*: 86-95.
2. Muzi, M.G., Maglio, R., Milito, G., et al. Long-term results of pilonidal sinus disease with modified primary closure: new technique on 450 patients. *Am Surg, 2014;80*: 484-488.
3. Meinero, P., La Torre, M., Lisi, G., et al. Endoscopic pilonidal sinus treatment (EPSiT) in recurrent pilonidal disease: a prospective international multicenter study. *Int J Colorectal Dis, 2019*. Doi: 10.1007/s00384-019-03256-8.
4. Humphries, A.E., Duncan, J.E. Evaluation and management of pilonidal disease. *Surg Clin North Am, 2010;90:*113-124.
5. McCallum, I., King, P.M., Bruce, J. (2007) Healing by primary versus secondary intention after surgical treatment for pilonidal sinus. Cochrane Database Syst Rev (4):CD006213 Review. Update in: Cochrane Database Syst Rev. 2010;(1):CD006213.
6. Emile, S.H., Elfeki, H., Shalaby, M. et al. Endoscopic pilonidal sinus treatment: a systematic review and meta-analysis. *Surg Endosc, 2018; 32*, 3754-3762.
7. Milone, M., Sosa Fernandez, L.M.,5 Manigrasso, M., et al. Pilonidal sinus and endoscopic surgery—myth or reality? *Ann Laparosc Endosc Surg, 2017;2*:175.
8. Angerer, C., Königsrainer, I. Endoscopic pilonidal sinus treatment (EPSiT). *Coloproctol, 2020;* 42, 345-352.
9. Meinero, P., Mori, L., Gasloli, G. Endoscopic pilonidal sinus treatment (E.P.Si.T.).

Tech. *Coloproctol, 2014; 18*(4):389-392.
10. Milone, M., Fernandez, L.M., Musella, M., et al. Safety and efficacy of minimally invasive video-assisted ablation of pilonidal sinus: a randomized clinical trial. *JAMA Surg, 2015; 151*(6):547-553.
11. Peksöz, R., Can, M. Endoscopic Pilonidal Sinus Treatment (EPST) Experience of a Provincial Hospital in Eastern Turkey. *Turk J Colorectal Dis, 2020;30*:173-178. Doi: 10.4274/tjcd.galenos.2020.2020.3.8.
12. Gecim, I.E., Goktug, U.U., Celasin, H. Endoscopic Pilonidal Sinus Treatment Combined With Crystalized Phenol Application May Prevent Recurrence. *Dis Colon Rectum. 2017;60*(4):405-407. Doi: 10.1097/DCR.0000000000000778. PMID: 28267008.
13. Steele, S.R., Perry, W.B., Mills, S., et al. Standards Practice Task Force of the American Society of Colon and Rectal Surgeons Practice parameters for the management of pilonidal disease. *Dis Colon Rectum, 2013; 56*(9):1021-1027. Doi: 10.1097/DCR.0b013e31829d2616
14. McCallum, I.J.D., King, P.M., Bruce, J. Healing by primary closure versus open healing after surgery for pilonidal sinus: systematic review and meta-analysis. *BMJ, 2008; 336*(7649):868-871. Doi: 10.1136/bmj.39517.808160.BE.
15. Garg, P., Menon, G.R., Gupta, V. Laying open (deroofing) and curettage of sinus as treatment of pilonidal disease: a systematic review and meta-analysis. *ANZ J Surg, 2016; 86*(1-2):27-33. Doi:10.1111/ans.13377.
16. Kayaalp, C., Ertugrul, I., Tolan, K., et al. Fibrin sealant use in pilonidal sinus: systematic review. *World J Gastrointest Surg ,2016;8*(3):266-273. Doi: 10.4240/wjgs.v8.i3.26626.
17. Kayaalp, C., Aydin, C. Review of phenol treatment in sacrococcygeal pilonidal disease. *Tech Coloproctol, 2009; 13*(3):189-193. Doi: 10.1007/s10151-009-0519-x.
18. Horwood, J., Hanratty, D., Chandran, P., e al. Primary closure or rhomboid excision and Limberg flap for the management of primary sacrococcygeal pilonidal disease? A meta-analysis of randomized controlled trials. *Color Dis, 2012; 14*(2):143-151.
19. Bali, İ., Aziret, M., Sözen, S., et al. Effectiveness of Limberg and Karydakis flap in recurrent pilonidal sinus disease. *Clinics (Sao Paulo), 2015; 70*(5):350-355.
20. Nordon, I.M., Senapati, A., Cripps, N.P. A prospective randomized controlled trial of simple Bascom's technique versus Bascom's cleft closure for the treatment of chronic pilonidal disease. *Am J Surg, 2009; 197*(2):189-192.