Revista da Sociedade Brasileira de Medicina Tropical
Journal of the Brazilian Society of Tropical Medicine
Vol.:59 | (e0241-2026) | 2026
https://doi.org/10.1590/0037-8682-0241-2026

Images in Infectious Diseases

Laryngeal tuberculosis mimicking a vallecular cyst: a diagnostic pitfall

Elif Gozgec[1] *and Emre Ozil*[1]

[1]. Ataturk University School of Medicine, Department of Radiology, Erzurum, Turkey.

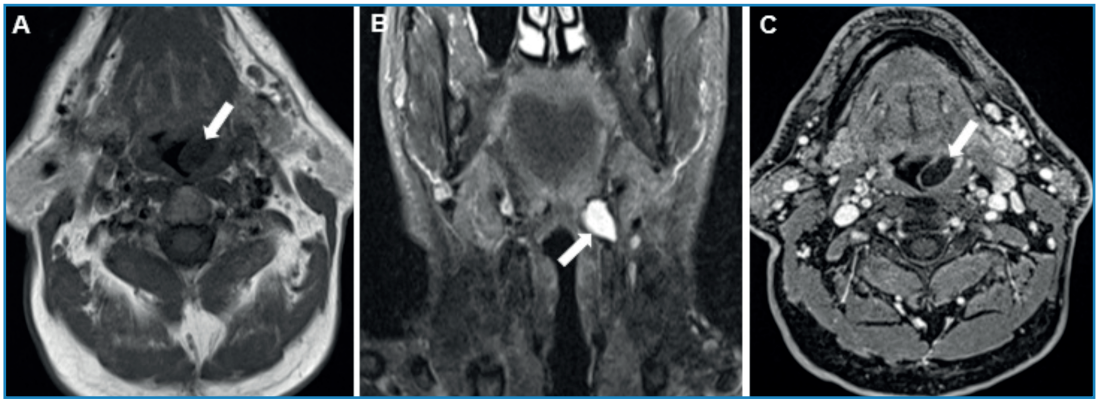

FIGURE 1: On magnetic resonance imaging, a cystic lesion (arrows) is observed in the left vallecular region: it appears hypointense in the T1-weighted axial image **(A)**, hyperintense in the T2-weighted coronal image **(B)**, and shows peripheral enhancement in the post-contrast axial series **(C)**.

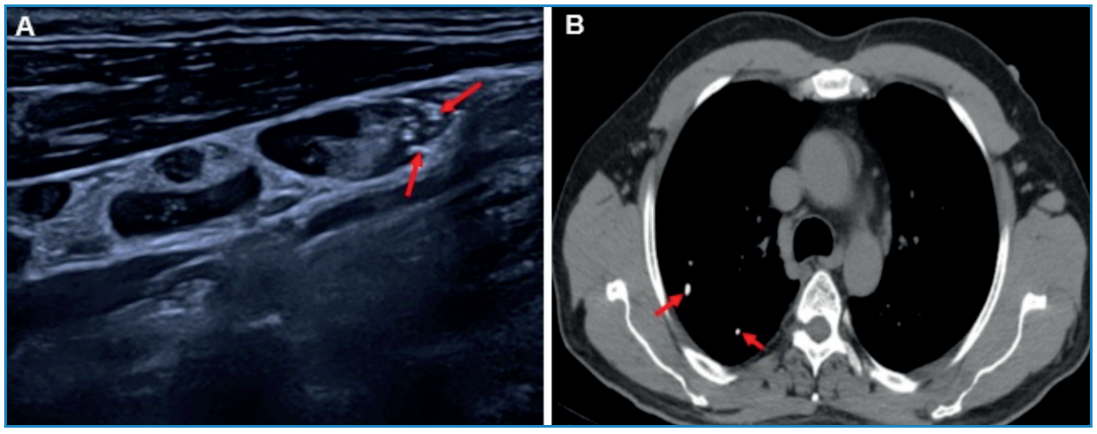

FIGURE 2: In the neck ultrasound image **(A)**, a lymph node with calcifications (arrows) is visible. In the non-contrast axial soft-tissue window chest CT image **(B)**, punctate calcifications (arrows) are visible in the right lung.

A 59-year-old male patient presented to the otorhinolaryngology clinic with hoarseness and difficulty swallowing that had persisted for approximately seven months. Laryngoscopic examination revealed a mass in the vallecula region at the oropharyngeal level. Pathologic examination of a 1-cc biopsy sample taken from this mass revealed findings consistent with granulomatous diseases, including tuberculosis. Magnetic resonance imaging demonstrated an 18 × 11 × 20 mm cystic lesion in the left vallecula, T2-hyperintense, T1-hypointense, with peripheral enhancement and increased diffusion (**Figure 1**). Multiple cervical lymph nodes with cortical thickening and diffusion restriction were also noted. Ultrasound revealed punctate calcifications in the left level III lymph nodes (**Figure 2A**). Interferon-gamma release assay and QuantiFERON-TB test results were positive. A subsequent chest computed tomography (CT) scan performed for screening purposes revealed changes in sequelae suggesting a history of tuberculosis (**Figure 2B**). Anti-tuberculous therapy was initiated.

Dr. Elif Gozgec. **E-mail:** elf.gvn@hotmail.com
Conflict of Interest Statement: The authors declare no conflicts of interest.
Financial Support: None.
Associated Editor: Prof. Manoel Otávio da Costa Rocha
Received 10 May 2026 - **Accepted** 24 June 2026

Laryngeal TB may present as an isolated, mass-like lesion with minimal or absent pulmonary findings. It is frequently confused with laryngeal carcinoma (cancer) due to shared symptoms including hoarseness, dysphagia, and mass-like lesions detected via laryngoscopy[1,2]. These shared symptoms create a diagnostic dilemma that may delay establishment of the correct diagnosis, even in regions where tuberculosis remains endemic[1]. Such atypical presentations should be kept in mind, particularly in endemic regions, and imaging should play a supportive role in diagnosis.

AUTHORS' CONTRIBUTION

EG: Conception and design of the study, Acquisition of data, Analysis and interpretation of data, Final approval of the version to be submitted; EO: Conception and design of the study, Acquisition of data, Drafting the article.

REFERENCES

1. Pandiyan H, Sivanand N, Sathish Kumar S. Isolated Laryngeal Tuberculosis: a Diagnostic Dilemma. Indian J Otolaryngol Head Neck Surg. 2022;74:2308-10. doi: 10.1007/s12070-020-02139-7. Epub 2020 Sep 10. PMID: 36452854; PMCID: PMC9702101.

2. Yammouri Z, Chaouche S, Alami G, Harmouch F, Alami B, Lamrani Y, et al. Laryngeal Tuberculosis Mimicking Laryngeal Carcinoma: A Case Report. Cureus. 2025;17(7):e87828. doi: 10.7759/cureus.87828. PMID: 40799900; PMCID: PMC12341445.

OPEN ACCESS