Revista da Sociedade Brasileira de Medicina Tropical
Journal of the Brazilian Society of Tropical Medicine
Vol.:59 | (e0480-2025) | 2026
https://doi.org/10.1590/0037-8682-0480-2025

Images in Infectious Diseases

Diffuse Pericardial and Diaphragmatic Involvement of Alveolar Echinococcosis in a Liver-Transplanted Patient

***Yener Aydin*[1], *Elif Gozgec*[2] *and Ugur Kaya*[3]**

[1]. Ataturk University, Medical Faculty, Department of Thoracic Surgery, Erzurum, Turkey.
[2]. Ataturk University, Medical Faculty, Department of Radiology, Erzurum, Turkey.
[3]. Ataturk University, Medical Faculty, Department of Cardiovascular Surgery, Erzurum, Turkey.

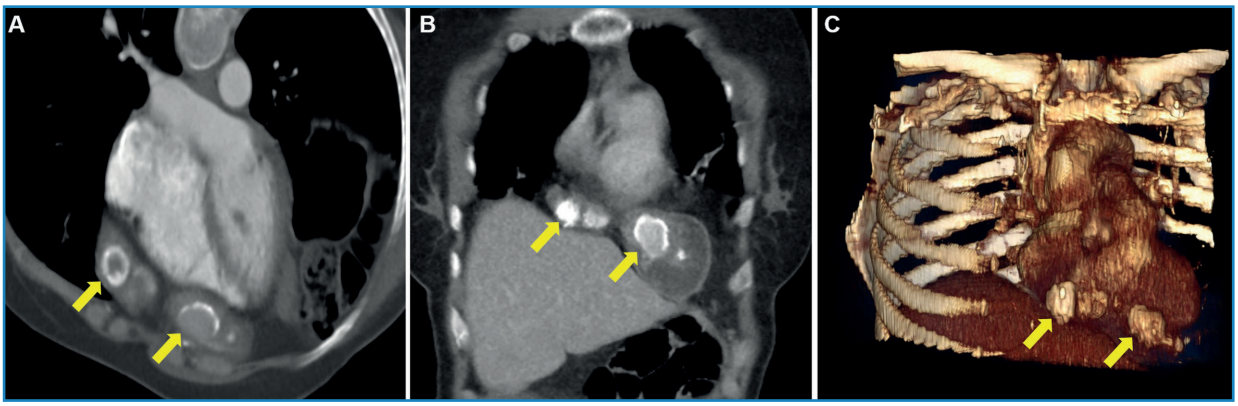

FIGURE 1: Contrast-enhanced thorax CT images obtained in the axial oblique **(A)** and coronal **(B)** planes, as well as 3D oblique anterior-posterior reconstruction images **(C)**, showing a central hyperdense lesion (arrows) in the pericardial area extending to the diaphragm.

A 40-year-old woman presented to our hospital with chest pain. She had undergone liver transplantation 5 years ago for alveolar echinococcosis. Radiological imaging revealed a hyperdense lesion in the pericardial area, characterized by dense calcified areas extending to the diaphragm (**Figure 1**). The patient underwent median laparotomy, and the lesion was resected en bloc with portions of the diaphragm and pericardium. The pericardial defect was reconstructed using the bovine pericardium, and the diaphragmatic defect was repaired using a Prolene mesh (Ethicon; Somerville, NJ, USA). Alveolar echinococcosis was confirmed histopathologically by identifying laminated membranes using periodic acid–Schiff (PAS) staining. The postoperative course was uneventful, and the patient was discharged on postoperative day 7.

Alveolar echinococcosis is a life-threatening parasitic disease caused by *Echinococcus multilocularis*, which primarily affects the liver. Early stage management relies on radical surgical resection combined with adjuvant chemotherapy to achieve the best outcomes; however, liver transplantation remains the only curative treatment for advanced alveolar echinococcosis[1,2]. Albendazole, the most widely used benzimidazole agent, is administered to prevent recurrence in surgically managed cases and to suppress parasitic growth in patients in whom surgery is not feasible[1]. In rare cases, recurrence of alveolar echinococcosis with calcified lesions can occur after transplantation, potentially involving extrahepatic sites[3]. Surgical resection should be considered as an effective approach for managing pleural and pericardial recurrences of alveolar echinococcosis after liver transplantation.

AUTHORS' CONTRIBUTION

YA: Conception and design of the study, Acquisition of data, Drafting the article, Final approval of the version to be submitted; EG: Conception and design of the study, Analysis and interpretation of data; UK: Conception and design of the study, Analysis and interpretation of data, Final approval of the version to be submitted.

REFERENCES

1. Aydin Y, Ogul H, Topdagi O, Ulas AB, Sade R, Ozturk G, et al. Relevance of Pulmonary Alveolar Echinococcosis. Arch Bronconeumol (Engl Ed). 2020;56(12):779-83.
2. Zhu M, Gao X, Wang X, Meng L. Multimodal imaging for the diagnosis of cardiac alveolar echinococcosis: a case report. BMC Cardiovasc Disord. 2025;25(1):107.
3. Aydin Y, Ulas AB, Aksungur N, Eroglu A. Surgical Approach in the Pulmonary Alveolar Echinococcus. Arch Bronconeumol. 2024;60(6):385-7.

Dr. Yener Aydin. **E-mail:** dryeneraydin@hotmail.com
Financial Support: None
Conflict of Interest: The authors declare no conflicts of interest.
Associated Editor: Manoel Otávio da Costa Rocha
Received 23 October 2025 – **Accepted** 10 December 2025

OPEN ACCESS