Journal of Clinical Anesthesia 55 (2019) 77–78

Contents lists available at ScienceDirect

Journal of Clinical Anesthesia

journal homepage: www.elsevier.com/locate/jclinane

Correspondence

Ultrasound guided erector spinae plane block for postoperative analgesia in a 13 year-old child undergoing abdominal surgery: A new approach

To the Editor;

Ultrasound provides the real-time imaging of nerves and their surrounding structures. So, it is becoming an important adjunct in regional anesthesia. The use of ultrasound in regional anesthesia allows the visualisation of the injectate entering the correct plane, increases rates of achieving a successful block, reduces complication rates as surrounding structures [1]. Erector Spinae Plane (ESP) block was first described by Forero et al. for thoracic neuropathic pain management. Local anesthetic is injected between the erector spinae muscle and transverse process under ultrasound guidance for this block and local anesthetic affects the dorsal and ventral rami of the thoracic and abdominal spinal nerves [2]. There are some cases reporting its use for different indications in adults and pediatrics while it has been defined for thoracic surgery [3,4].

Although the ESP block is performed at thoracic level by a linear probe placed longitudinally [3], it is possible to perform the ESP block from the lumbar level using new described "Aksu" approach [5] to have effective postoperative analgesia in pediatric abdominal surgery. Herein; we would like to report a bilateral ESP block at lumbar level in which successful postoperative analgesia was obtained. In this report, written informed consent of the patient's parent was obtained for using data of the child.

A 13-year-old, 33 kg, male, American Society of Anesthesiologists (ASA) physical status I patient was scheduled for laparoscopic hepatic hydatid cystectomy. After standart monitorization, general anesthesia was performed for surgical procedure. Propofol 2 mg/kg, rocuronium 0.6 mg/kg and 2 μg/kg fentanyl was used for anesthesia induction and sevoflurane 2–3% was used for the anesthesia maintenance.

Bilateral ESP was performed under general anesthesia before surgical procedure. Patient placed left and right lateral position respectively and bilateral ESP block was done at the level of L 2–3 vertebrae under ultrasound guidance (Xperius™ - B. Braun). After antiseptic preparation, a curved probe placed transversely at the level of L 2–3 and tried to view vertebral body, transverse process and erector spinae muscle. After identifying these anatomical structures, a 22G, 100 mm needle (BBraun Sonoplex, Melsungen, Germany) was used for block and local anesthetic injection was done between the erector spinae muscle and transverse process (Fig. 1). Same procedure was performed for the other side and spread of local anesthetic was seen between erector spinae muscle and transverse process. After the surgery, patient was transferred to the post-anesthetic care unit (PACU) and pain scores were evaluated by using a visual analog scale (VAS). According to our postoperative pain management procedure, 15 mg/kg paracetamol iv was administered every 6 h. During postoperative 24 h, patient did not need any rescue analgesic.

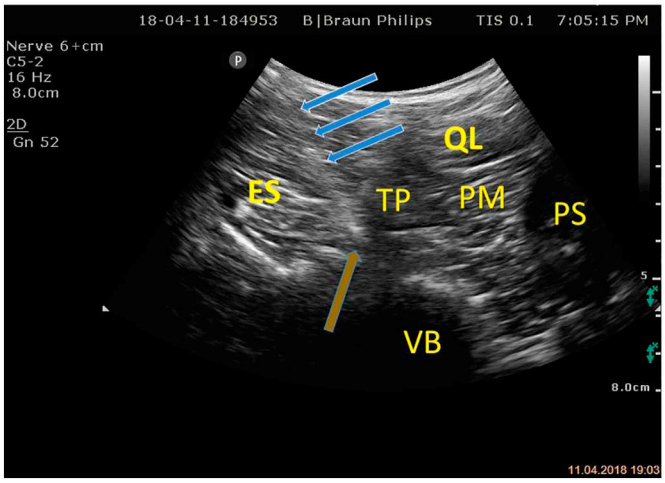

Fig. 1. Ultrasonographic image of anatomical structures. QL: Quadratus lumborum muscle, PM: Psoas muscle, PS: Posterior surface, ES: Erector spinae muscle, TP: Transverse process, VB: Vertebral body.

https://doi.org/10.1016/j.jclinane.2018.12.016
Received 11 December 2018; Accepted 14 December 2018
0952-8180/ © 2018 Elsevier Inc. All rights reserved.

The method we first described in this case provides us with the following advantages:

1. Because of difficulties of prone position under general anesthesia, this new approach can be preferable.
2. The needle can be controlled and directed more easily and this increases the safety of ESP block which is done for abdominal surgery in pediatric patient.
3. Anatomic structures can be more visible and understandable.

Besides of these reports, we still need additional case reports and studies to prove this new approach success and safety.

Declarations of interest

None.

Financial support

No financial support existing.

References

[1] Gerrard C, Roberts S. Ultrasound-guided regional anaesthesia in the paediatric population. ISRN Anesthesiology 2012:1–8.
[2] Forero M, Adhikary SD, Lopez H, Tsui C, Chin KJ. The erector spinae plane block: a novel analgesic technique in thoracic neuropathic pain. Reg Anesth Pain Med 2016;41:621–7.
[3] Tulgar S, Senturk O. Ultrasound guided erector spinae plane block at L-4 transverse process level provides effective postoperative analgesia for total hip arthroplasty. J Clin Anesth 2018;44:68.
[4] Aksu C, Gürkan Y. Ultrasound guided erector spinae block for postoperative analgesia in pediatric nephrectomy surgeries. J Clin Anesth 2018 Mar;45:35–6.
[5] Aksu C, Gürkan Y. Aksu approach for lumbar erector spinae plane block for pediatric surgeries. J Clin Anesth 2018 Nov 5;54:74–5.

Ilker Ince[a,b,*], Mehmet Aksoy[a], Ozgur Ozmen[a]
[a] *Department of Anesthesiology and Reanimation, Faculty of Medicine, Ataturk University, Erzurum, Turkey*
[b] *Department of Outcomes Research, Anesthesiology Institute, Cleveland Clinic, Cleveland, OH, USA*
E-mail address: incei@ccf.org (I. Ince).

[*] Corresponding author at: Ataturk University Faculty of Medicine, Yakutiye Research Hospital, Department of Anesthesiology and Reanimation, 2500 Yakutiye, Erzurum, Turkey.