The PHILIPPINE JOURNAL OF Veterinary Medicine

Original Article

The Impact of Laying Hen Hybrids and Cage Density on Keel Bone Damage

Ayşe Uysal[1], Ekrem Laçin[1], Soner Uysal[2]*

[1]Department of Animal Science, Faculty of Veterinary Medicine, University of Atatürk, Erzurum-25240, Türkiye
[2]Department of Animal Nutrition and Nutritional Diseases, Faculty of Veterinary Medicine, Ataturk University, Erzurum 25100, Türkiye

ORCİDs: A.U. 0000-0003-2803-2410; E.L. 0000-0002-8417-6710; S.U. 0000-0003-0372-9895;

[*] Correspondence: mrsvetayse@gmail.com (Ayşe Uysal)

This is an open access article under the CC BY 4.0 license (https://creativecommons.org/licenses/by/4.0/).

Submitted: 9 April 2024 Revised: 29 May 2024 Accepted: 25 June 2024 Published: 11 July 2024

Abstract

Background: The aim of this study was to examine the effect of cage density and hybrid variety on keel bone damage in laying hens. Methods: In this study, two different hybrids (Hy-line Brown, HB; Isa Tinted, IT) were used and 3 different cage densities low (750 cm^2/hen), medium (535.71 cm^2/hen) and high (375 cm^2/hen) were applied. The research started at the age of 20 weeks and continued until the chickens were 60 weeks old. In the research, 396 chickens (198 HB, 198 IT) and 54 cages were used. Laying hens were grouped by weight prior to cage placement. At the end of the experiment, the body weights of the chickens were measured. Additionally, a total of 54 randomly selected chickens (27 HB, 27 IT) were slaughtered to determine keel bone damage. After euthanization, the skin over the chest area was removed, and the chest structure was examined. The keel bone of the chicken, whose chest area was examined, was removed and scored. The chest area was scored as present or absent for hematoma. A score of "0" was given if no deviation or other damage was present in the chest area. A score of "1" was assigned if there was deviation or other damage (thickened) in the chest area. The keel bone was scored as follows: "0" for no damage, "1" for mild deviation, "2" for moderate deviation or thickening, and "3" for severe deviation or fracture. Results: According to the results of the research, hematoma in the chest area was observed more at low cage density ($P<0.001$). Additionally, as a result of scoring the chest area and keel bone; it was determined that the most damage was in HBs ($P<0.001$). Cage density did not affect body weight. Moreover, keel bone damage was found to be more severe in Hy-line Brown hens compared to Isa Tinted hens ($P<0.001$). Conclusion: In conclusion, keel bone damage was observed more in low cage density and Hy-line brown hybrids.

Keywords: Cage density, Hybrid, Keel bone damage, Scoring, Welfare.

1. Introduction

Keel bone damage (KBD; deviation, fracture) is one of the most important welfare problems in commercial laying hybrids [1]. Additionally, keel bone damage is of economic importance in laying hens [2]. Laying hens may face KBD at the rate of 5.5% at the beginning of the spawning period, and it may raise to the rate of 97% at the end of the spawning period [3-8]. KBD causes pain, soreness and limited movement in hens, as well as a decline in yield performance [4, 9]. Moreover, it has been reported that chickens with KBD may experience a decrease in egg production and egg quality, thinning of the eggshell, a decrease in the breaking strength of the eggshell, and decrease in egg weight [2].

The keel bone consists of three areas, cranial, medium, and caudal [10, 11]. Ossification of the caudal end of the keel bone may not be completed until 30-40 weeks of age [12]. Therefore, the first area to be affected by trauma is the caudal end of the keel bone, both due to its anatomical location and cartilage structure [11].

Many factors can affect the occurrence of KBD in laying hens, such as age, genetics, rearing system and perch [13-19]. It has been stated that keel bone damage generally increases with age [4]. In terms of genetics, it has been stated that keel bone damage is generally more common in brown laying hens than in white laying hens [20]. Since chickens are freer in cage-free rearing systems than in caged systems, collisions or trauma are more likely to occur. For this reason, studies have shown that damage is greater in cage-free systems [6, 21]. Chickens apply pressure to the chest area while roosting. In this case, perch has a significant impact on the occurrence of keel bone damage [20]. However, compared to other factors, of these factors, the cultivation system and equipment have a greater impact on KBD [5, 13, 22]. Alternative rearing systems, although providing optimum conditions for the welfare of chickens, carry risks for KBD [15]. Additionally, rearing systems using perch pose a greater risk for KBD [23, 24]. In general, histological analysis shows that moderate and severe keel injuries are caused by trauma [17].

Cage density applied in rearing systems is directly related to the animal's behavior and therefore its welfare [25-28]. Rising cage density also brings welfare problems such as keel bone damage in chickens. Because with rising cage density, chickens have difficulty changing their position and the pressure on the chest area increases [29].

One of the other factors affecting KBD is hybrid. In general, it is stated that since brown hybrids are heavier than white hybrids, keel bone damage is more common. Because hybrids with high weight put more pressure on the chest area while perching or resting, which causes keel bone damage [6, 18, 20, 31, 32].

Studies on keel bone damage have been mostly carried out in alternative cage systems. However, the Türkiye layer poultry industry is generally carried out in conventional cage systems. The aim of this study is to examine the status of keel bone damage by creating different cage density in conventional systems. In addition, the effect of hybrid on keel bone damage is still a subject open to research. Therefore, in this study, the effect of cage density and hybrid on keel bone damage was investigated.

2. Materials and Methods

2.1. Hybrid and Experiment Design

Hy-line Brown (HB) and Isa Tınted (IT) laying hybrids of the same age were used as animal material in the study. A total of 396 laying hybrids, 198 HB and 198 IT, were used. Three different cage densities were created in the conventional cage system. Hybrids were housed at cage densities of 5 hens/cage (750 cm^2/hen), 7 hens/cage (535.71 cm^2/hen), and 10 hens/cage (375 cm^2/hen). In addition, laying hens with similar body weights were randomly selected and placed in cages. The cage densities were numbered by forming subgroups of these groups with 9 replications (total of 54 cages). The dimensions of the cages used in the experiment are equal to each other. These cage dimensions are front height 51 cm, rear height 46 cm, width 62.5 cm, depth 60 cm. In the cages, there is a 7° slope and a total of 2 water nipples that will allow the egg to fall on the egg band. Egg collection and feeding in the henhouse is done once a day by automatic equipment. The manure in the henhouse is transferred to the manure discharge band through the moving bands under each cage and removed from the henhouse. A lighting period of 16 hours of light and 8 hours of darkness is applied in the henhouse. Ventilation takes place through fans and windows operating under the negative pressure effect.

2.2. Processing and Sample Preparation

This study started with laying hens at 20 weeks old and ended when the birds reached 60 weeks old. At the end of the experiment, a total of 396 hybrids in the whole cage were weighed according to the cage number. All of the chickens in each cage were put in a cardboard box and weighed and the average was taken. After weighing, the chickens were given a one-day rest period and slaughtered. For slaughter, a total of 54 hybrids were selected, one randomly from each cage. Slaughter was carried out in the poultry slaughtering unit located right

next to the Poultry Unit. The cutting process was carried out by the same person and from the same area. During slaughter, chickens were taken to the slaughterhouse one by one, considering the welfare of the chickens. The slaughtered chickens were laid on an empty table after 2-3 minutes of bloodletting. In order to avoid confusion between the groups, the feet were numbered with a permanent pen. Later, the skin of the chest area of the chickens were removed one by one and scoring process was done. After the table was filled, the skin of the chest area of the chickens were removed one by one and scoring was made by only one person. After the chest area was evaluated in terms of well-being, scoring was performed on the keel bone obtained from the chest area by the same observer.

2.3. Welfare Assessment

2.3.1. Chest Area

The technique of Heerkens et al., (2016) [32] was used for scoring hematomas in the chest area. In this technique, scoring was done by a single observer as present or absent according to the presence of hematoma (Figure 1). Deviation scoring over the chest area was also performed by the same observer. In the scoring of the chest area, the visual in figure 2 was used. A score of "0" was given if no deviation or other damage was present in the chest area. A score of "1" was assigned if there was deviation or other damage (thickened) in the chest area.

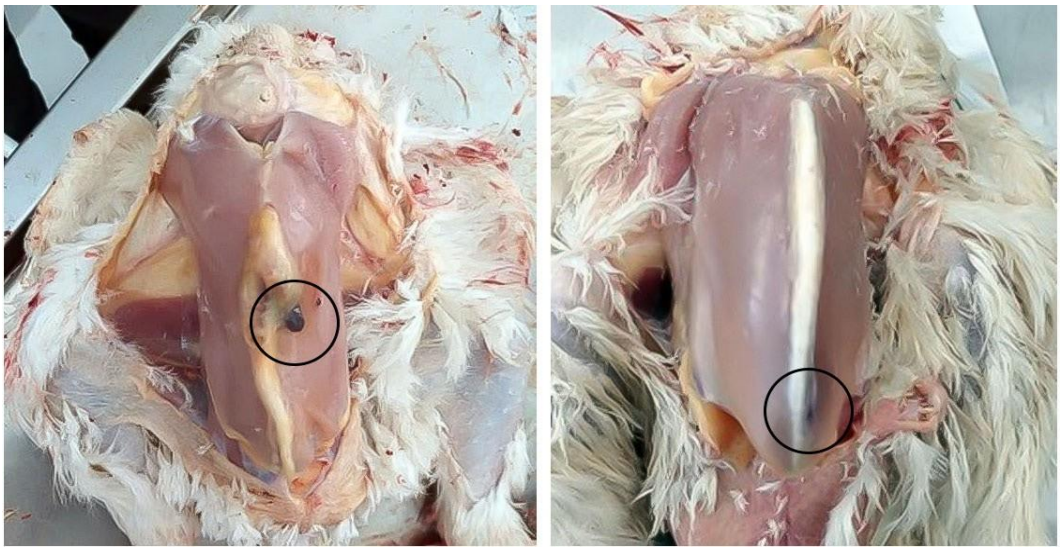

Figure 1. Hematoma formation in the chest area.

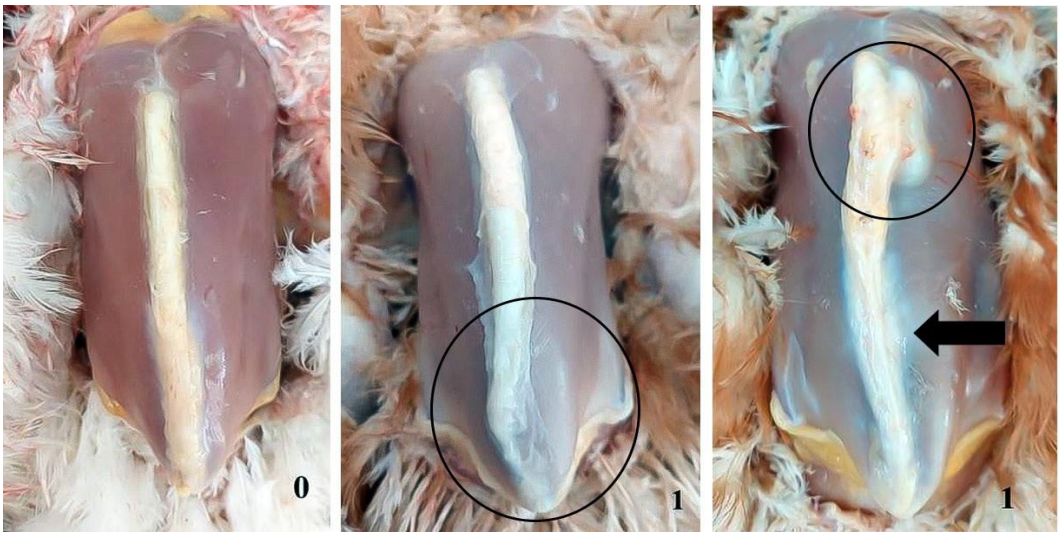

Figure 2. Deviation scoring in the chest area (0: flat keel bone; 1: deviated or thickened keel bone).

2.3.2. Keel Bone/Sternum

After the chest area of the chicken was evaluated, the keel bone was removed and the tissues on it were removed. Again by the same observer, KBD (deviation, fracture, thickening) scoring was performed on the bone. The visual in Figure 3 was used for scoring. The keel bone was scored as follows: "0" for no damage, "1" for mild deviation, "2" for moderate deviation or thickening, and "3" for severe deviation or fracture.

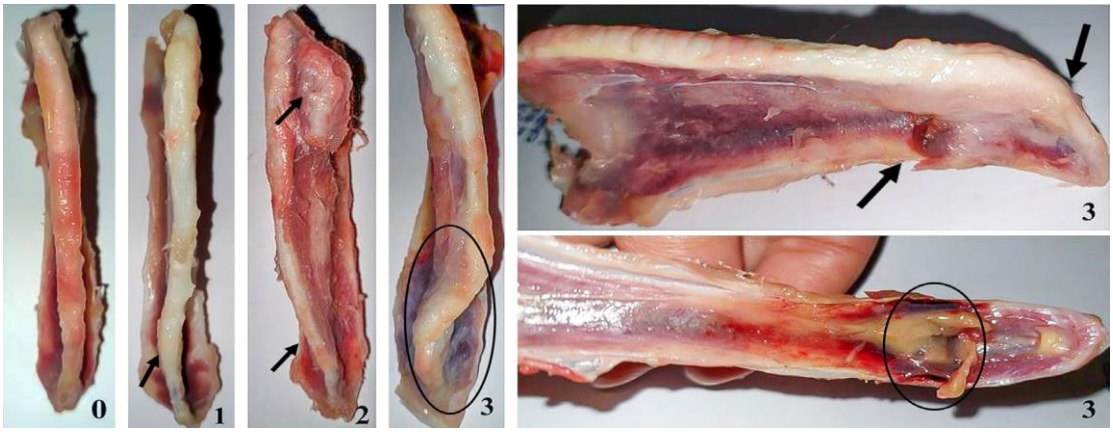

Figure 3. Keel bone damage scoring (0; straight and undamaged, 1; slightly deviated, 2; moderate deviation or thickening, 3; severe deviation or fracture).

2.4. Statistical Analysis

SPSS 25.0 software (SPSS Inc, Chicago, USA) was used to In the analysis of the data obtained from the study. It was determined that the data was continuous. The chi-square test, one of the non-parametric tests, was used to determine the effects of independent factors such as cage density and hybridity on KBD. Spearman's correlation test was performed to determine the relationship between body weight of hybrids, KBD and hematoma values.

3. Results

3.1. Hematoma (Chest)

The results of hematoma conditions in HB and IT, depending on the cage density, are shown in Table 1. When the results are examined, it was found that the effect of hybrid and cage density on hematoma was statistically important ($p<0.001$). The highest hematoma was observed in the group of laying hybrids at low cage density (0.78). In addition, it was expressed that hematoma was more common in HB than in IT in all groups.

Table 1. Effect of cage density and hybrid on hematoma

Cage Density	Hybrid	Mean	SEM
Low	HB	0.88	0.14
	IT	0.67	0.14
Total		0.78[a]	0.25
Medium	HB	0.56	0.14
	IT	0.11	0.14
Total		0.33[b]	0.25
High	HB	0.44	0.14
	IT	0.00	0.14
Total		0.22[b]	0.22
		P	
Cage		**	
Hybrid		**	

Low: 5 hens/cage; medium: 7 hens/cage; high: 10 hens/cage HB: Hyline Brown; IT: Isa Tınted **important ($P<0.001$); [a,b]values within a row with different superscripts differ significantly at $P<0.001$)

3.2. Deviation or Other Damage (Thickened) (Chest)

Depending on the cage density of the groups, the deviation in the HB and IT is given in Figure 4. When the results are examined, it was observed that the damage was more in HB, but there was no statistical difference between the two hybrids ($p>0.05$). In addition, when the effect of the cage density on the damage was examined, it was determined that the damage was more in the low cage density, but there was no statistical difference between these groups ($p>0.05$).

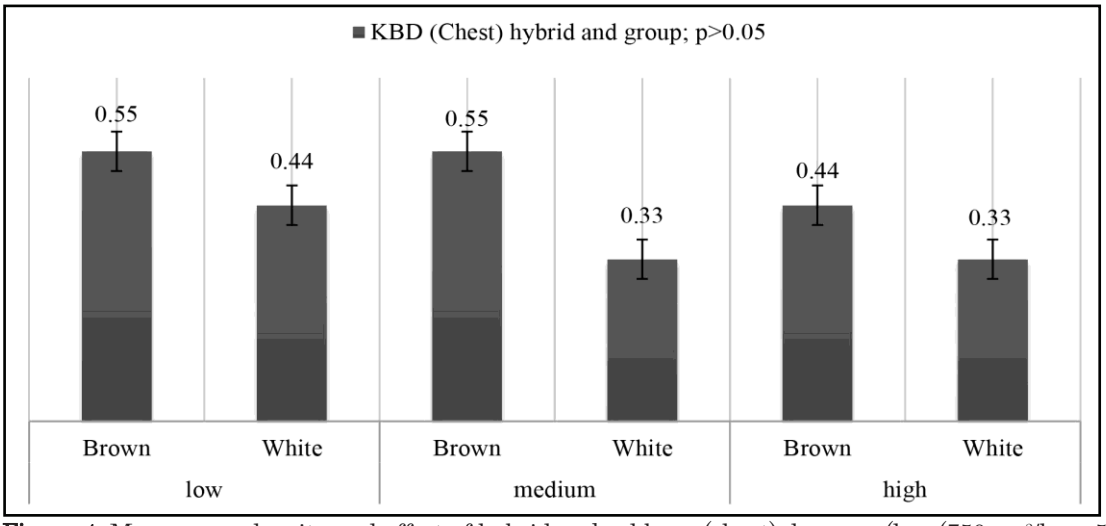

Figure 4. Means cage density and effect of hybrid on keel bone (chest) damage, (low (750 cm^2/hen; 5 hens/cage), medium (535.71 cm^2/hen; 7 hens/cage) and high (375 cm^2/hen; 10 hens/cage), group: cage density, Brown: Hy-line Brown, White: Isa Tınted.

3.3. Body Weight

Average body weight values of hybrids housed in different groups are given in Table 2. When the results are examined, it was found that there was no statistical difference between the groups in terms of body weight ($p>0.05$), but HB had higher body weight than IT ($p<0.001$).

Spearman's correlation results of body weight, KBD and hematoma values in HB and IT laying hybrids are shown in Table 3. When the results are examined, it was determined that there was a significant and highly positive correlation (0.318) between the body weight values and the formation of hematoma. On the other hand, it was observed that there was a positive correlation (0.20-0.25) between KBD-hematoma values and body weight, and this was statistically insignificant.

Table 2. Body weights of HB and IT at 60 weeks

Cage Density	Hybrid	Mean	SEM
Low	HB	2174.00	37.29
	IT	1779.00	50.04
Medium	HB	2152.88	37.29
	IT	1818.20	50.04
High	HB	2066.33	37.29
	IT	1700.00	50.04
		P	
Cage		NS	
Hybrid		**	

Low: 5 hens/cage; medium: 7 hens/cage; high: 10 hens/cage; HB: Hyline Brown; IT: Isa Tınted
**important ($P<0.001$); NS: not significant

Table 3. Spearman's correlation (chest)

	Body weight	KBD	Hematoma
Body weight	1		
KBD	0.2	1	
Hematoma	0.318**	0.25	1

KBD: Keel bone damage **important (P<0.001)

3.4. Keel Bone Damage

The results indicating the of cage density and the effect of hybrid on KBD (deviation, thickening, fracture) are given in Figure 5. When the results are examined, it was expressed that the group with the highest damage had a low cage density, but this situation was insignificant according to the statistical results (p>0.05). In addition, it was determined that the HB had more KBD than the IT (p<0.01).

4. Discussion

This research was carried out to determine the impact of different density and hybrid created in conventional cage systems on KBD. According to the research results, it was determined that these factors may affect KBD.

4.1. Impact of Cage Density on KBD

In the present study, welfare assessment in laying hybrids was made both by looking at the chest and by removing and examining the keel

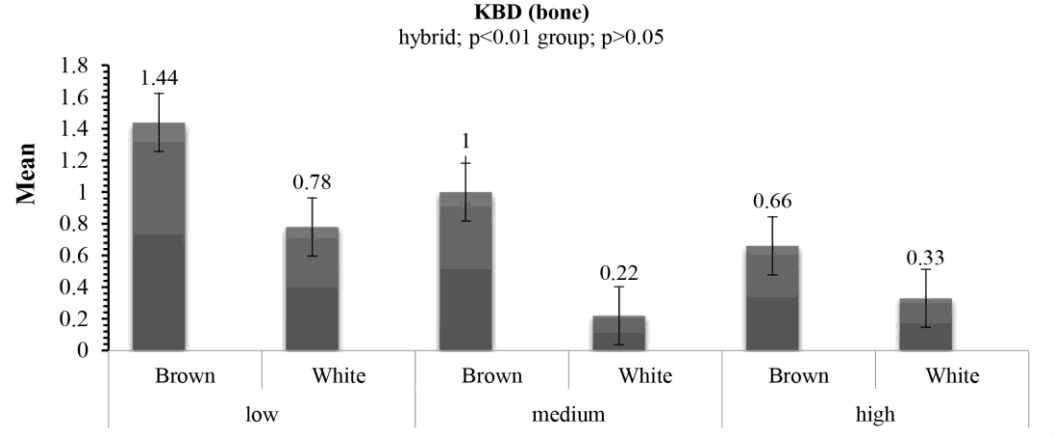

Figure 5. Means cage density and effect of hybrid on keel bone damage (bone), (low (750 cm²/hen; 5 hens/cage), medium (535.71 cm²/hen; 7 hens/cage) and high (375 cm²/hen; 10 hens/cage); group: cage density; Brown: Hy-line brown; White: Isa Tınted.

Table 4. Spearman's correlation (bone)

	Body Weight	KBD
Body weight	1	
KBD	0.274	1

KBD: Keel bone damage

3.5. Spearman's Correlation

Spearman's correlation results between body weight and KBD values are shown in Table 4. When the results are examined, it was observed that there was a positive correlation (0.274) between the body weight-KBD values, but this difference was not statistically significant.

bone. The hematoma in the chest area differed between groups and hybrids. More hematomas were observed in the hybrids housed in the low cage density group compared to the hybrids in the other groups. Hybrids housed at low cage densities might have had more collisions with cage equipment or with each other because they were more free in terms of movement than other groups. In a study by Heerkens et al., in 2016 [32], it is estimated that findings such as hematoma or wound in the chest area, as in

this study, are caused by collision. More studies are needed to better understand the impact of cage density on the welfare of laying hens. In this way, the effect of cage density on keel bone damage will be further clarified.

It was determined that the cage density was not effective on the damage to the chest area and keel bone. Another study reached similar results to the current study; They found that the cage density applied in enriched systems had no effect on keel bone damage [19]. Geng et al., in 2020 [33] found that chickens had the highest mortality rates in high cage density; they found their welfare quality to be the lowest. In other studies, it was determined that cage density did not affect keel bone status [17, 34, 35]. Due to the density of cages, chickens are housed in a narrow environment. However, the basis of the damage generally lies in trauma. For this reason, the effect of cage density on keel bone damage may not be significant. In order to further elucidate the issue, chickens need to be raised and researched in different cage densities.

In studies examining keel bone damage, the effect of rearing systems rather than the effect of cage density on keel bone damage has been examined. In a study investigating the effect of conventional cage systems and enriched cage systems on KBD, it was reported that the damage rate was higher in enriched cage systems [36]. Kajlich et al., in 2015 [37] reported that since the chickens are freer in cage-free systems, more damage is seen than in caged systems. In a study comparing enriched cages, floor system, and free-range systems in terms of KBD, it was reported that the highest damage was in free-range systems [38, 39] determined that conventional cages are the system with the lowest keel bone fracture in conventional cages, furnished cages, floor systems, single-tier systems, and aviaries systems. However, Casey-Trott et al., in 2017 [4] in a study comparing the aviary system and conventional cage systems, they found that the keel bone fracture was less common in aviary systems and keel bone deviation was less common in conventional systems.

4.2. Impact of Hybrid on KBD

In the current study, it was determined that hematoma in the chest area was higher of HBs than in ITs. Additionally, the effect of the hybrid on damage to the chest area wasnegligible; Its effect on the keel bone was significant (more on Hy-line Browns). Since the body weight of HBs is higher than ITs, it can be thought that the pressure on the chest area is greater and therefore the damage is more severe. Similar to the results of the current study, Fawcett et al., in 2020 [20] stated in their study that keel bone fracture is more common in brown hybrids than in white hybrids. This result is due to the fact that brown hybrids have lower navigational skills; browns were also associated with higher body weight. In another study, Lohmann Brown Classic hybrids has been found fewer caudal end fractures compared to Isa Brown hybrids [30]. In general, research results have shown that keel bone damage is higher in brown hybrids [31, 36]. They thought that bone strength, the way of sitting on the perch, and body weight might cause this difference. In another study, when hybrids with high performance and low performance were examined in terms of keel bone fracture; more KBD was found in high-performance hybrids [13]. Habig et al., in 2021 [2] stated that keel bone damage was more common in high-yield white laying hens. They associated this result with white chickens being more fearful and more active. In their studies, Uitdehaag et al., in 2009 [40] and Dudde et al., in 2018 [41], stated that white chickens face more keel bone damage due to their more fearful and combative nature. Chew et al., in 2021 [42] and Eusemann et al., in 2018 [7] in their study, argued that there was no difference between brown and white hybrids in terms of KBD. When the results of the research were examined, there was no consensus on whether the brown hybrids are more sensitive than the white hybrids in terms of KBD. Therefore, more scientific research is needed examining the effect of genetics on keel bone damage. In this way, by determining a hybrid that is resistant to keel bone damage, it can be used in production and higher yields can be obtained.

4.3. Impact of Body Weight on KBD

According to the results of the research, there was no difference in body weight between the groups (5 hens/cage, 7 hens /cage, and 10 hens/cage) when examination was carried out on the basis of cage density. The reason why there is no difference between groups in terms of body weight may be due to the lack of available data. Through examination on a hybrid basis, it was determined that HB had higher body weights than IT. Contrary to the current study, it has been reported that hybrids housed in dense cage density are lighter in terms of body weight compared to hybrids housed under standard conditions [43]. In another study, it is stated that the body weight will decrease with the increase in the cage density and the in the size of the herd [44]. In the present study, a positive relationship was found between KBD and body weight interactions. This may be associated with the higher live weight of brown chickens. Habig et al., in 2021 [2] stated in their study that there was a significant positive relationship between KBD and body weight interactions and reached a similar conclusion with the current study. Thofner et al., in 2021 [43], which resulted in a similar finding, found that less keel bone fractures occurred in milder hybrids in their study. Eusemann et al., in 2018 [7] and Eusemann et al., in 2020 [13] in their study, reported the deviations in the keel bone increase with the increase in body weight and

supported the current study result. In addition, in this study, it was argued that there was a risk for KBD, as the increase in body weight would increase the severity of collisions in hybrids. In another study, it was stated that chickens with keel bone fracture had lower body weight, and they reached the opposite conclusion with the current study [19]. Contrary to all these studies, Kolakshyapati et al., in 2019 [46] in a study, found that body weight was not effective on keel bone fracture. When studies on the subject are examined, live weight is generally a threatening factor for keel bone damage. However, some studies have stated the opposite. Therefore, there is a need for studies revealing the relationship between body weight and keel bone damage in order to improve the welfare quality of chickens.

5. Conclusions

As a result, low cage density increased hematoma formation in the chest area. Hy-line Brown hybrids were found to have higher body weight compared to Isa Tinted hybrids. Additionally, more damage was seen in Hy-line Brown hybrids. Welfare quality has an important place for the productivity of laying hens. Therefore, more research is needed on the welfare of laying hens.

Author Contributions

E.L. and A.U. experiment was designed. S.U. and A.U. collected the data. E.L. performed the statistical analyses. S.U. and A.U. raised funds and A.U. wrote the article. S.U. and E.L. reviewed and accepted the article.

Ethics Approval and Consent to Participate

This study was carried out in the Poultry Unit of Erzurum Atatürk University Food and Livestock Research and Application Center. The study was approved by Atatürk University Veterinary Faculty Unit Ethics Committee (decision number: 2022/26; decision date: 26.08.2022).

Acknowledgments

This study was supported by Atatürk University Scientific Research Projects Coordination Unit as project number TSA-2021-9527.

Conflict of Interest

No potential conflict of interest was reported by the author(s).

References

[1] Jung, L., Hillemacher, S., Tiemann, I., Lepke, M., & Hinrichs, D. (2024). Presence of keel bone damage in laying hens, pullets and roosters of local chicken breeds. Plos one, 19(1), e0297586.

[2] Habig, C., Henning, M., Baulain, U., Jansen, S., Scholz, AM., and Weıgend, S. (2021). Keel bone damage in laying hens—its relation to bone mineral density, body growth rate and laying performance. Animals, 11 (6):15-46.

[3] Wılkıns, lJ., Mckınstry, JL., Avery, NC., Knowles, TG., Brown, SN., Tarlton, J., and Nıcol, CJ. (2011). Influence of housing system and design on bone strength and keel bone fractures in laying hens. Veterinary Record, 169 (16):414-414.

[4] Casey-trott, TM., Guerın, MT., Sandılands, V., Torrey, S., and Widowskı, TM. (2017). Rearing system affects prevalence of keel bone damage in laying hens: a longitudinal study of four consecutive flocks. Poultry Science, 96 (7):2029-2039.

[5] Harlander-Matauschek, A., Rodenburg, TB., Sandilands, V., Tobalske, BW., and Toscano, MJ. (2015). Causes of keel bone damage and their solutions in laying hens. World's Poultry Science Journal, 71 (3):461-472.

[6] Stratmann, A., Frohlıch, EK., Harlander-Matauschek, A., Schrader, L., Toscano, MJ., Würbel, H., and Gebhardt-Henrıch, GS. (2015). Soft perches in an aviary system reduce ıncidence of keel bone damage in laying hens. Plos One, 10 (3):122-568.

[7] Eusemann, BK., Baulaın, U., Schrader, L., Thöne-reıneke, C., Patt, A., and Petow, S. (2018). radiographic examination of keel bone damage in living laying hens of different strains kept in two housing systems. Plos One, 13 (5):194-974.

[8] Uzunova, K., and Lazarov, L. (2020). Damages of the keel bone in laying hens–overview of the etiological aspects. Trakia Journal of Sciences. 18 (1):19-23.

[9] Chargo, NJ., Robıson, CI., Baker, SL., Toscano, MJ., Makagon, MM., and Karcher, DM. (2019). Keel bone damage assessment: consistency in enriched colony laying hens. Poultry science, 98 (2):1017-1022.

[10] Baur, S., Rufener, C., Toscano, MJ., and Geissbühler, U. (2020). Radiographic evaluation of keel bone damage in laying hens—morphologic and temporal observations in a longitudinal study. Frontiers in Veterinary Science, 7:129.

[11] Saraıva, S., Esteves, A., and Stılwell, G. (2019). Influence of different housing systems on prevalence of keel bone lesions in laying hens. Avian Pathology, 48 (5):454-459.

[12] Toscano, MJ., Dunn, IC., Chrıstensen, JP., Petow, S., Kıttelsen, K., and Ulrıch, R. (2020). Explanations for keel bone fractures in laying hens: are there explanations in addition to elevated egg production? Poultry Science, 99 (9):4183-4194.

[13] Eusemann, BK., Patt, A., Schrader, L., Weıgend, S., Thöne-Reıneke, C., and Petow, S. (2020). The role of egg production in the etiology of keel bone damage in laying hens. Frontiers in Veterinary Science, 7(81).

[14] Rıber, AB., and Hınrıchsen, LK. (2016). Keel-bone damage and foot injuries in commercial laying hens in Denmark. Animal Welfare, 25 (2):179-184.

[15] Hardin, E., Castro, FLS., and Kim, WK. (2019). Keel bone injury in laying hens: the prevalence of injuries in relation to different housing systems, implications, and potential solutions. World's Poultry Science Journal, 75 (2):285-292.

[16] Saraıva, S., Esteves, A., Olıveıra, I., and Stılwell, G. (2020). Assessment of fear response and welfare ındicators in laying hens from barn systems. Livestock Science, 240:104-150.

[17] Habig, C., & Distl, O. (2013). Evaluation of bone strength, keel bone status, plumage condition and egg quality of two layer lines kept in small group housing systems. British poultry science, 54(4), 413-424.

[18] Kıttelsen, KE., Gretarsson, P., Jensen, P., Chrıstensen, JP., Toftaker, I., Moe, RO., and Vasdal, G. (2021). Keel bone fractures are more prevalent in white leghorn hens than in red jungle fowl hens a pilot study. Plos One, 16 (7):255-234.

[19] Weı, H., Chen, NH., Wang, J., Lıu, Y., Wang, J., and Bao, J. (2021). Abnormal bone metabolism may be a primary causative factor of keel bone fractures in laying hens. Animals, 11 (11):31-33.

[20] Fawcett, DL., Casey-Trott, TM., Jensen, L., Caston, LJ., and Wıdowskı, TM. (2020). Strain differences and effects of different stocking densities during rearing on the musculoskeletal development of pullets. Poultry Science, 99 (9):4153-4161.

[21] Spiridonovic S, Djukic-Stojcic M, Peric L, Pajic M and Knezevic S (2021). Welfare parameters and keel bone damage in laying hens reared in different production systems. Biotechnology in Animal Husbandry 37 (2): 109–116.

[22] Laçın, E., and Kureksız, A. (2020). Keel bone damage in laying hens. Journal of Poultry Research, 17 (2):50-55.

[23] Petek, M. and Çavuşoğlu, E. (2021). Welfare assessment of two free-range laying hen flocks in turkey. Journal of Applied Animal Welfare Science, 24 (1):56-63.

[24] Sandilands, Vicky. (2014). Perch designs for alternative egg-producing systems. http://www.keelbonedamage.eu/wp-content/uploads/KBW-perch-recommendations-Aug14.pdf . accessed 12 September 2022.

[25] Hanh, H.Q., Phuong, N.T., Tien, ND., Nhung, DT., Lebailly, P., & Ton, VD. (2023). Effects of Stocking Density in Group Cages on Egg Production, Profitability, and Aggressive Pecking of Hens. Journal of Applied Animal Welfare Science, 26(3), 374-385.

[26] EFSA Panel on Animal Health and Animal Welfare (AHAW), Nielsen, SS., Alvarez, J., Bicout, DJ., Calistri, P., Canali, E., ... & Michel, V. (2023). Welfare of laying hens on farm. EFSA Journal, 21(2), e07789. https://doi.org/10.2903/j.efsa.2023.7789

[27] Özentürk U, Yildiz A, Murat, G (2022). Assessment of the feather score and health score in laying hens reared at different cage densities. Ankara Üniversitesi Veteriner Fakültesi Dergisi 70 (1): 1-8.

[28] Özenturk U and Yildiz A (2021). Comparison of performance parameters, stress, and immunity levels of native and commercial layers reared in different cage densities in Turkey. Turkish Journal Of Veterinary & Animal Sciences 45 (6): 1052-1064.

[29] Wan, Y., Guan, H., Wang, D., Ma, R., Qi, R., Li, J., ... & Zhan, K. (2023). Effects of cage stocking density on the production performance, serum biochemistry, immune level, and intestinal morphology of 2 laying hen breeds. Journal of Applied Poultry Research, 32(4), 100375.

[30] Heerkens, JLT., Delezıe, E., Ampe, B., Rodenburg, TB., and Tuyttens, FAM. (2016). Ramps and hybrid effects on keel bone and foot pad disorders in modified

aviaries for laying hens. Poultry Science, 95 (11):2479-2488.

[31] Vıts, A., Deitzenburger, W., Hamann, H., and Distl, O. (2005). production, egg quality, bone strength, claw length, and keel bone deformities of laying hens housed in furnished cages with different group sizes. Poultry Science, 84 (10):1511-1519.

[32] Heerkens, JLT., Delezıe, E., Rodenburg, TB., Kempen, I., Zoons, J., Ampe, B., and Tuyttens, FAM. (2016). Risk factors associated with keel bone and foot pad disorders in laying hens housed in aviary systems. Poultry Science, 95 (3):482-488.

[33] Geng, AL., Lıu, HG., Zhang, Y., Zhang, J., Wang, HH., Chu, Q., and Yan ZX. (2020). Effects of indoor stocking density on performance, egg quality, and welfare status of a native chicken during 22 to 38 weeks. Poultry Science, 99 (1):163-171.

[34] Jensen, L. (2019). The effects of stocking density on the growth, behaviour, and welfare of layer pullets in two cage systems (Doctoral dissertation, University of Guelph).

[35] Jung, L., Niebuhr, K., Hinrichsen, L. K., Gunnarsson, S., Brenninkmeyer, C., Bestman, M., ... & Knierim, U. (2019). Possible risk factors for keel bone damage in organic laying hens. Animal, 13(10), 2356-2364.

[36] Scholz, B., j Kjaer, B., and Schrader, L. (2014). Analysis of landing behaviour of three layer lines on different perch designs. British Poultry Science, 55 (4):419-426.

[37] Kajlıch, AS., Shivaprasad, HL., Trampel, DW., Hıll, AE., Parsons, RL., Mıllman, ST., and Mench, JA. (2015). Incidence, severity, and welfare ımplications of lesions observed postmortem in laying hens from commercial noncage farms in california and ıowa. Avian Diseases, 60 (1):8-15.

[38] Dedousı, A., Stojcıc, MD., and Sossıdou, E. (2020). Effects of housing systems on keel bone damage and egg quality of laying hens. Veterinary Research Forum, 11 (4):299.

[39] Rufener, C., and Makagon, MM. (2020). Keel bone fractures in laying hens: a systematic review of prevalence across age, housing systems, and strains. Journal of Animal Science, 98 (1):36-51.

[40] Uıtdehaag, KA., Rodenburg, TB., Bolhuıs, JE., Decuypere, E., and Komen, H. (2009). Mixed housing of different genetic lines of laying hens negatively affects feather pecking and fear related behaviour. Applied Animal Behaviour Science, 116 (1):58-66.

[41] Dudde, A., Schrader, L., Weıgend, S., Matthews, LR., and Krause, ET. (2018). More eggs but less social and more fearful? differences in behavioral traits in relation to the phylogenetic background and productivity level in laying hens. Applied Animal Behaviour Science, 209:65-70.

[42] Chew, J., Wıdowskı, T., Herwıg, E., Shynkaruk, T., and Schwean-lardner, K. (2021). The effect of light ıntensity on the body weight, keel bone quality, tibia bone strength, and mortality of brown and white feathered egg-strain pullets reared in perchery systems. Poultry Science, 100 (11):101-464.

[43] Ozenturk, U., and Yıldız, A. (2020). Assessment of egg quality in native and foreign laying hybrids reared in different cage densities. Brazilian Journal of Poultry Science, 22.

[44] Nıcol, CJ., Brown, SN., Glen, E., Pope, SJ., Short, FJ., Warrıss, PD., and Wılkıns, WJ. (2006). Effects of stocking density, flock size and management on the welfare of laying hens in single-tier aviaries. British Poultry Science, 47 (2):135-146.

[45] Thofner, IC., Dahl, J., and Chrıstensen, JP. (2021). Keel bone fractures in danish laying hens: prevalence and risk factors. Plos One, 16 (8):256-105.

[46] Kolakshyapatı, M., Flave,l RJ., Sıbanda, TZ., Schneıder, D., Welch, MC., and Ruhnke, I. (2019). Various bone parameters are positively correlated with hen body weight while range access has no beneficial effect on tibia health of free-range layers. Poultry Science, 98 (12):6241-6250.