Journal of Cardiothoracic and Vascular Anesthesia 35 (2021) 2094–2099

Contents lists available at ScienceDirect

Journal of Cardiothoracic and Vascular Anesthesia

journal homepage: www.jcvaonline.com

Original Article

# Syringe-Free, Long-Axis in-Plane Versus Short-Axis Classic out-of-Plane Approach for Ultrasound-Guided Internal Jugular Vein Catheter Placement in Critically Ill Children: A Prospective Randomized Study

Halil Keskin, Assistant Professor[*,†,1], Filiz Keskin, MD[‡], Pelin Aydin, MD[§], Muhammet Akif Guler, Assistant Professor[¶], Ali Ahiskalioglu, Associate Professor[†,‖]

[*]*Department of Pediatric Intensive Care Unit, Ataturk University School of Medicine, Erzurum, Turkey*
[†]*Clinical Research, Development and Design Application and Research Center, Ataturk University School of Medicine, Erzurum, Turkey*
[‡]*Department of Pediatric Neurology, Ataturk University School of Medicine, Erzurum, Turkey*
[§]*Department of Anesthesiology and Reanimation, Erzurum State Hospital, Erzurum, Turkey*
[¶]*Department of Pediatric Nephrology, Ataturk University School of Medicine, Erzurum, Turkey*
[‖]*Department of Anesthesiology and Reanimation, Ataturk University School of Medicine, Erzurum, Turkey*

*Objective:* Although pediatric central venous catheterization is performed using ultrasound guidance, it is still a challenge. This study aimed to investigate the efficacy of the syringe-free, long-axis in-plane approach and compared the short-axis classic out-of-plane approach for ultrasound-guided central venous catheter placement in critically ill pediatric patients.
*Design:* Prospective randomized study.
*Setting:* Single institution, tertiary university hospital, pediatric care unit.
*Participants:* The study comprised 60 patients ages three months to 15 years.
*Interventions:* Participants were randomly divided into two equal groups. Group I (n = 30) incorporated patients who underwent the long-axis, syringe-free in-plane approach, and group II (n = 30) incorporated patients who underwent the short-axis out-of-plane approach.
*Measurements and Main Results:* Performing time, number of needle passes, number of skin punctures, first-pass success rate, and related complications were evaluated. There were no differences between the two groups in terms of demographics and vein-related measurements ($p > 0.05$). Performing time was statistically shorter in group I compared with group II (32 [25-38] *v* 58 [42-70] s; $p < 0.001$). There was no statistical difference between first-pass success rates between groups (group I 86.6% *v* group II 80%; $p = 0.731$). There were no significant differences between the groups in the number of needle passes and skin punctures ($p = 0.219$ and 0.508, respectively). Complications occurred in both groups, but there was no significant difference (4/30 *v* 7/30; $p = 0.317$).
*Conclusions:* The syringe-free, long-axis in-plane approach can be a safe and fast alternative for pediatric catheterization.
© 2021 Elsevier Inc. All rights reserved.

*Key Words:* syringe-free; long-axis in-plane; short-axis out-of-plane; ultrasound; central venous catheter

EVEN THOUGH the first central venous catheter (CVC) placement in humans was reported in the 1920s, the Seldinger method, making catheter placement easier and safer, began to be used in the early 1950s.[1] With the introduction of ultrasound (US) into clinical use through developing technologies,

[1]*Address correspondence to* Halil Keskin, MD, Department of Pediatric Intensive Care Unit, Ataturk University School of Medicine, 25070, Erzurum, Turkey.
*E-mail address:* keskinpediatrize@gmail.com (H. Keskin).

https://doi.org/10.1053/j.jvca.2021.03.029
1053-0770/© 2021 Elsevier Inc. All rights reserved.

US-guided methods have become indispensable and have been used for many years.[2] US guidance has increased the success of CVC placement and has resulted in the reduction of the number of access attempts and many related complications.[3-11]

The success of the procedure and development of possible complications directly depend on patient anatomy, comorbid conditions, and skill of the operator.[7,8] The smaller anatomic structure of pediatric patients compared with adults makes US-guided CVC placement more challenging in these patients.

For CVC placement, internal jugular, subclavian, or femoral veins usually are used.[12] Regardless of the vein preferred, the Seldinger technique is the most frequently adopted method,[13] and the most commonly used method in US-guided procedures is the short-axis out-of-plane approach. The greatest problem with this method is the inability to identify the true tip position of the needle, which can cause posterior wall punctures, resulting in the development of certain complications such as hematoma formation, malposition, nerve injury, and arterial puncture.[14] In contrast, the syringe-free technique, first described by Matias et al.,[15] allows for real-time full US monitoring of the guidewire insertion into the vein without blood aspiration.

To the authors' knowledge, even though studies have compared the long-axis in-plane with the traditional short-axis out-of-plane approach in pediatric patients,[16] the literature contains no randomized controlled study on pediatric CVC placement with a syringe-free method other than a case series in which brachiocephalic vein catheterization was performed in children.[17]

The present study's primary aim was to compare the performing time of these two techniques in critically ill children who required CVC placement. Secondary aims were first-pass success rate, number of needle passes, number of skin punctures, and complications.

## Materials and Methods

### *Patients and Study Design*

After obtaining approval from the Local Ethics Committee of Ataturk University Faculty of Medicine, a total of 60 patients, ages three months to 15 years, who had been admitted to the pediatric intensive care unit and had an indication for CVC were included in the study. The study was registered with a clinical trial registry (ClinicalTrials.gov NCT04684069). The study was designed as a randomized prospective study. Detailed information about the methods to be applied was given to the parents or custodians of all patients, and their written consent was obtained. Patients younger than three months and older than 15 years; those weighing <5,000 g; those with any anatomic malformation in the neck, infection at the intervention site, or thrombosis detected by US; those with a history of internal jugular vein catheterization; and those whose parents did not provide consent for participation in the study were excluded.

Routine monitoring (electrocardiogram, peripheral oxygen saturation, noninvasive blood pressure) was applied to the patients in the pediatric intensive care unit. A pediatrician (H. K.) blinded to all other procedures randomly divided the patients into two equal groups according to a random list created using a computer randomization program (Microsoft Office 365 Excel with the "RAND" function; Microsoft, Redmond, WA) before the intervention.

All catheterizations were performed using the right jugular vein by one pediatric intensive care physician with at least two years of experience in US (H.K.). The patient's head was rotated about 45 degrees to the left, a rolled towel was placed under the neck, and the patient was placed in the Trendelenburg position of about 15-to-20 degrees. Furthermore, the same USG device (Toshiba, Aplio 500 Ultrasound Systems; Toshiba, Tokyo, Japan) and high-frequency micro-convex probe were used for all patients. After catheterization, the catheter location was confirmed using chest x-ray in both groups.

In the first group (syringe-free group), long axis in-plane CVC access was achieved with the syringe-free method under US guidance. The USG probe was covered with a sterile sheath after gel was applied all around. The internal jugular vein and carotid artery then were visualized by placing the probe transverse to the triangle formed by the clavicular and sternal legs of the sternocleidomastoid muscle. After the veins were visualized in the transverse position, the US probe was turned to the long axis, and the internal jugular vein was imaged. Subsequently, the internal jugular vein was confirmed with collapsibility and Doppler. A guidewire-adapted needle (Certofix Trio; B Braun, Melsungen, Germany) was advanced into the vein by the proceduralist during live US visualization. Then, when the needle entered the vein lumen, the guidewire adapted to the needle was advanced in-plane into the internal jugular vein using full real-time US. The guidewire position was confirmed in the internal jugular vein and is seen as a "dot" on the short axis. No other clinician took part in advancing the guidewire (Fig 1, *A* and *B*).

In the second group (conventional method group), CVC was performed using the conventional US method in the short axis with the out-of-plane approach. A sterile sheath was placed on the US probe after the gel was applied all around. The probe then was placed in the triangle formed by the clavicular and sternal legs of the sternocleidomastoid muscle. The needle was advanced into the anterior wall of the vein using the out-of-plane technique with US guidance (Fig 1, C and D). After the needle was visualized as a hyperechoic point at the central point of the vein, blood flow was confirmed by aspiration. The syringe was removed from the needle, then a guidewire was inserted the vein. Successful guidewire placement was verified with US in the long-axis view.

### *Outcomes*

Successful catheterization was defined as the insertion of the guidewire into the internal jugular vein within ten minutes, which was confirmed with US. The performing time was defined as the time between the insertion of the needle through the skin and insertion of the guidewire into the internal jugular vein. The number of attempts needed to enter the jugular vein,

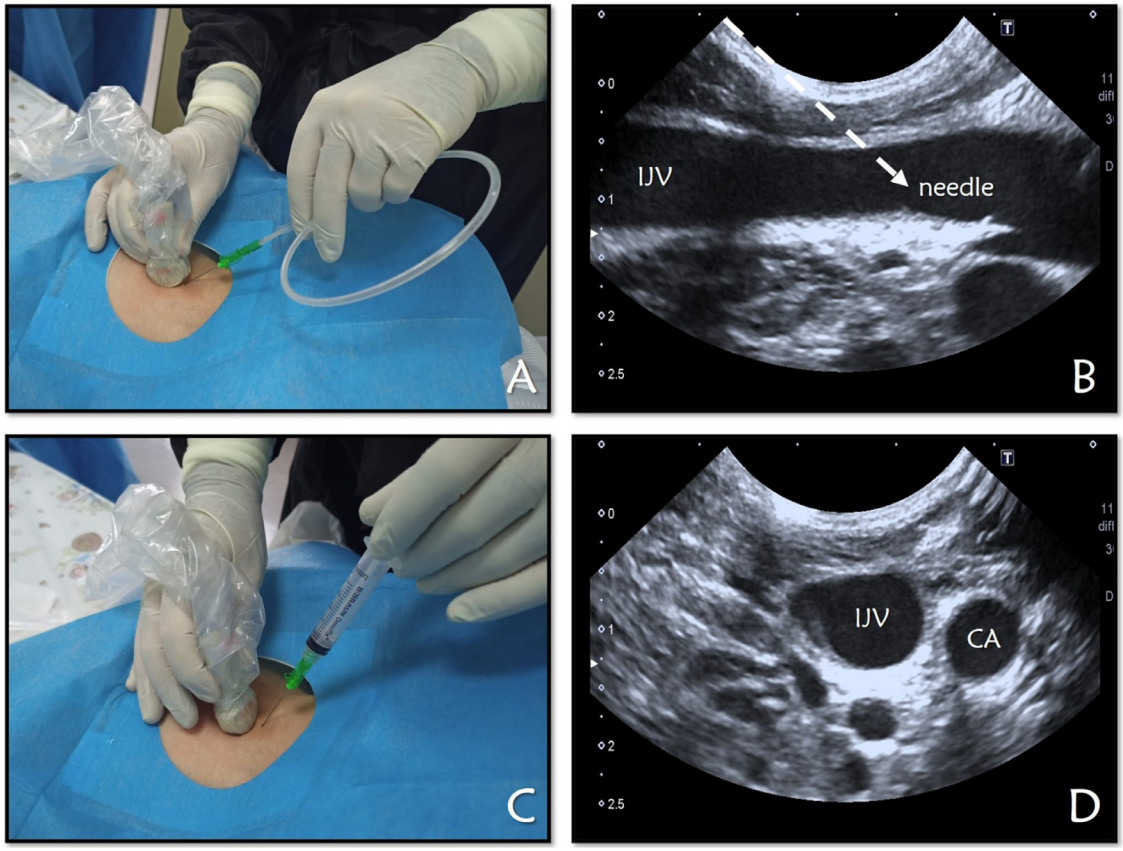


Fig 1. (A) Patient and needle orientation for the syringe-free, long-axis in-plane approach with a guidewire-adapted needle. (B) Sonoanatomic structures for a long-axis in-plane approach. (C) Patient and needle orientation for the short-axis out-of-plane approach. (D) Sonoanatomic structures for the short-axis out-of-plane approach. CA, carotid artery; IJV, internal jugular vein.

the first-pass success rate, the number of redirections, and the number of punctures were recorded. A needle pass was defined as the advancement of the needle without a backward movement. The first-pass success rate was defined as successful catheterization with only one needle pass. The number of redirections (needle passes) was defined as the number of changes made to the needle direction without pulling the entire needle through the skin. A new puncture was defined as the withdrawal of the needle from the skin to change the puncture site. Complications such as arterial puncture, pneumothorax, hematoma, and cannulation failure were noted. In addition, demographic data, transverse venous diameter, and subcutaneous venous depth (anterior wall of the short-axis vein) were recorded before the procedure.

### *Sample Size and Statistical Analyses*

The sample size calculation was based on the primary aim of the study (ie, performing time). A preliminary study indicated that the performing time should be 37.86 ± 13.12 seconds in the syringe-free group (n = seven) and 57.29 ± 29.46 seconds in the conventional method group (n = seven). A total sample size of 26 patients for each group was calculated using G*Power, Version 3.1.9.2 (Heinrich-Heine-University, Düsseldorf, Germany) with a two-tailed test, an alpha probability of 0.05, a power of 0.85, and an effect size of 0.852. Considering possible dropouts, the authors decided to include at least 30 patients in each group.

Statistical analysis was performed using SPSS Statistics, Version 22.0 (IBM, Armonk, NY). Normal distribution of data was assessed with the Kolmogorov-Smirnov test. Descriptive statistics included mean values with standard deviation or proportions, depending on the characteristics of the data. Continuous variables are expressed as mean ± standard deviation or median (interquartile range) values. The groups were compared using the *t* test for normally distributed data, and the Mann-Whitney *U* test was used for skewed data. Nominal variables were compared using the chi-square or Fisher exact test. A p value $<0.05$ was considered to be statistically significant.

## Results

A total of 75 patients were evaluated for eligibility during the study period. After 15 patients were excluded, the data of a total of 60 patients were analyzed (Fig 2). There was no significant difference between the groups in terms of the demographic data of patients, namely age, height, weight, sex, body mass index, catheter size, and vein-related measurements ($p > 0.05$) (Table 1).

Table 2.

Performing time was significantly shorter in the syringe-free group compared with the conventional method group (32 [25-

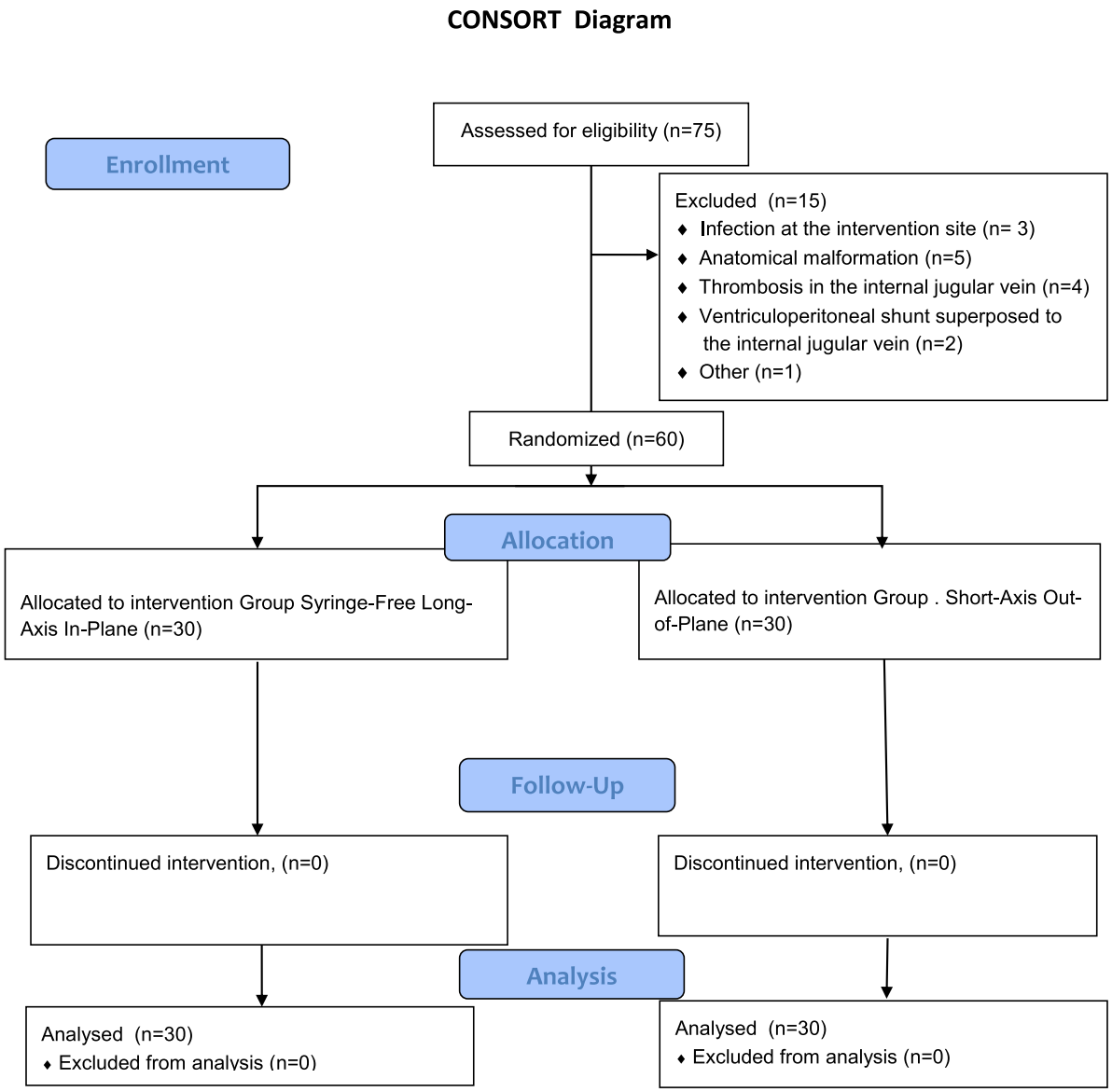


Fig 2. CONSORT flow chart of the study.

38] *v* 58 [42-70] s; $p < 0.001$). However, there was no significant difference between the two groups in terms of the first-pass success rates (86.6% *v* 80%, respectively; $p = 0.731$). In addition, no differences were observed between the groups in relation to the number of needle passes and skin punctures ($p = 0.219$ and $p = 0.508$, respectively). Although complications were seen in both groups, there was no significant difference. Complications were observed in four patients in the syringe-free group (hematoma in three and carotid puncture in one) and in seven patients in the conventional method group (hematoma in three, carotid puncture in two, and posterior wall puncture in two) ($p = 0.317$) (Table-2).

## Discussion

The present study showed that the long-axis, syringe-free in-plane approach significantly reduced performing time in CVC placement. There were no differences between the two groups in terms of the number of needle passes, number of skin punctures, first-pass success rate, and complications. These results suggested that the syringe-free, long-axis in-plane approach is a safe and fast alternative method for pediatric catheterization.

The concept of the global use of US has been used to acknowledge the role of US in procedures in many different aspects, from planning to performing venous access and definition of early and late complications.[3,4,9,18,19] Providing a safe vein pathway in pediatric resuscitation is a critical step in the success of resuscitation. Ensuring vascular access within the first few minutes increases the likelihood of the success of resuscitation. Even in experienced hands, both venous and arterial cannulations are difficult processes, particularly in children. Especially with the use of US, this procedure has become easier and many complications have been prevented. While performing US-guided cannulation, optimal imaging

Table 1
Demographic Characteristics of the Study Groups

| | Group I (Syringe-Free) (n = 30) | Group II (Conventional Method) (n = 30) | p |
|---|---|---|---|
| Age (mo) | 61 (12-115) | 45.50 (10-112) | 0.750* |
| Sex (male/female) | 14/16 | 15/15 | 0.796† |
| Height (cm) | 101.50 (64-131) | 98.50 (65-130) | 0.734* |
| Weight (kg) | 17.50 (6.50-28) | 21 (8.90-30) | 0.657* |
| Body mass index | 15.57 (14.26-17.80) | 16.60 (14.80-18.70) | 0.158* |
| Catheter size, 3/5/7 Fr | 5/18/7 | 5/17/8 | 0.953† |
| Intubated (yes/no) | 24/6 | 20/10 | 0.243† |
| Subcutaneous venous depth (mm) | 10 (6-12) | 9 (6-11) | 0.666* |
| Transverse venous diameter (mm) | 8 (5-9) | 8 (6-10) | 0.917* |

NOTE. All values are presented as median (interquartile range) or number.
* Mann-Whitney *U* test.
† Chi-square test.

and needle guidance techniques vary on the basis of the operator, but they all are of great importance in facilitating the procedure.[20]

The most preferred method for internal jugular vein catheterization in children is the short-axis out-of-plane approach. Because of the small vein diameters, posterior wall puncture is more common in pediatric patients than in adults. In a study conducted with children <5 kg, the long-axis in-plane approach was reported to be highly effective in preventing posterior wall puncture.[16] However, this is not a frequently used approach in pediatric patients. The short neck, in particular, has limited the use of this method because of the general inaccessibility of an appropriately sized US probe.[16] Because a US probe suitable for the size of children was used in the present study, no compliance problem with this method was observed. Especially in young children, interventions performed with a micro-convex probe have increased the success rate. In the present study, the operator who performed the procedure had been using the short-axis out-of-plane approach for many years. After a short-term orientation training, he easily adapted to the use of the long-axis in-plane approach. Unlike other studies,[21,22] the authors of the present study attributed the lack of difference in posterior wall puncture between the two groups to the experience of the operator.

Table 2
Comparison of Outcomes Between the Groups

| | Syringe-Free (n = 30) | Conventional Method (n = 30) | p |
|---|---|---|---|
| Performing time (s) | 32 (25-38) | 58 (42-70) | <0.001* |
| First-pass success (yes/no) | 26/4 (86.6%) | 24/6 (80%) | 0.731† |
| Number of needle passes | 1 (1-1) | 1 (1-2) | 0.219* |
| Number of skin punctures | 1 (1-1) | 1 (1-1) | 0.508* |
| Complications (yes/no) | 4/26 | 7/23 | 0.317† |
| Hematoma | 3 | 3 | 1.000† |
| Carotid puncture | 1 | 2 | 1.000† |
| Posterior wall puncture | 0 | 2 | 0.492† |

NOTE. All values are presented as median (interquartile range) or number.
* Mann-Whitney *U* test.
† Fisher exact test.

The main advantage of the syringe-free approach is that the in-plane long-axis needle insertion guarantees maintaining the whole needle under real-time visualization and decreasing the risk of misplacement of the needle tip throughout cannulation (referred to as "full real-time US" in the present study). The proceduralist holds both the needle and the attached guidewire in one hand as a single set of instruments while the other hand is used to operate the USG during the procedure. This process ensures subsequent installation of the guidewire into the vein without any undesired movements of the needle after the vein is punctured. The syringe-free approach adapted to the long-axis in-plane approach combines the advantages of the two methods. However, it should not be forgotten that the success of the procedure in both methods still depends on the experience and skill of the operator.

It is possible to state that the time difference between the two methods would have no significance in elective cases. However, in emergency situations such as resuscitation, every second is too important to be discussed in terms of resuscitation success. In recent years, the intraosseous approach for emergency settings has been used widely in pediatrics.[23] At the initiation of resuscitation, intraosseous and peripheral venous access should simultaneously be attempted. Even if peripheral venous or intraosseous access is provided, central venous access will be required for continuous drug administration, blood sampling, and monitoring after the resuscitation. The in-plane, syringe-free technique also may be an alternative in femoral vein catheterization in a cardiac arrest situation, during which chest compressions are ongoing, to minimize pauses in compressions. For this reason, the syringe-free technique for vascular access can be an appropriate alternative in such emergency situations provided it is performed by an experienced operator.

The use of the short-axis in-plane approach in the syringe-free method was investigated previously in adults.[24] The authors of the present study consider that in the short-axis in-plane approach with a syringe-free adaptation has a limited contribution because it cannot be confirmed in real time that the guidewire is moving in the correct axis.

The present study had certain limitations. First, it was not a double-blinded study by design. Second, the study was conducted with a relatively small sample in a single center, limiting the generalizability of the findings. Third, all interventions were performed by a single physician to ensure consistent results and external validity. Fourth, although choosing the US probe according to the patient's age may have increased the success of cannulation, this may not be possible in all pediatric

patients under all circumstances. Lastly, the required sample size was calculated according to performing time; therefore, although the initial success rate was higher in the syringe-free group, it was not statistically significant. In a larger series, this difference may be significant. Another limitation can be considered as the exclusion of patients younger than three months and weighing <5,000 g. There is greater difficulty with pediatric CVC placement in neonates and infants. Additional studies are needed to investigate the applicability of this method for younger and low-weight children.

## Conclusion

The syringe-free, long-axis in-plane approach is a safe and effective alternative to the short-axis out-of-plane approach, which is the most commonly used method for pediatric catheterization.

## Conflict of Interest

The authors declare no conflicts of interest.

## Supplementary materials

Supplementary material associated with this article can be found in the online version at doi:10.1053/j.jvca.2021.03.029.

## References


1 Higgs ZC, Macafee DA, Braithwaite BD, et al. The Seldinger technique: 50 years on. Lancet 2005;366:1407–9.
2 Randolph AG, Cook DJ, Gonzales CA, et al. Ultrasound guidance for placement of central venous catheters: A meta-analysis of the literature. Crit Care Med 1996;24:2053–8.
3 Biasucci DG, La Greca A, Scoppettuolo G, et al. What's really new in the field of vascular access? Towards a global use of ultrasound. Intensive Care Med 2015;41:731–3.
4 Bouaziz H, Zetlaoui PJ, Pierre S, et al. Guidelines on the use of ultrasound guidance for vascular access. Anaesth Crit Care Pain Med 2015;34:65–9.
5 Lamperti M, Bodenham AR, Pittiruti M, et al. International evidence-based recommendations on ultrasound-guided vascular access. Intensive Care Med 2012;38:1105–17.
6 Levy JA, Noble VE. Bedside ultrasound in pediatric emergency medicine. Pediatrics 2008;121:e1404–12.
7 McGee DC, Gould MK. Preventing complications of central venous catheterization. N Engl J Med 2003;348:1123–33.
8 Oliver WC Jr, Nuttall GA, Beynen FM, et al. The incidence of artery puncture with central venous cannulation using a modified technique for detection and prevention of arterial cannulation. J Cardiothorac Vasc Anesth 1997;11:851–5.
9 Pittiruti M. Ultrasound guided central vascular access in neonates, infants and children. Curr Drug Targets 2012;13:961–9.
10 Pittiruti M, Hamilton H, Biffi R, et al. ESPEN guidelines on parenteral nutrition: Central venous catheters (access, care, diagnosis and therapy of complications). Clin Nutr 2009;28:365–77.
11 Troianos CA, Hartman GS, Glas KE, et al. Special articles: Guidelines for performing ultrasound guided vascular cannulation: Recommendations of the American Society of Echocardiography and the Society of Cardiovascular Anesthesiologists. Anesth Analg 2012;114:46–72.
12 Lau CS, Chamberlain RS. Ultrasound-guided central venous catheter placement increases success rates in pediatric patients: A meta-analysis. Pediatr Res 2016;80:178–84.
13 Hsu CC, Kwan GN, Evans-Barns H, et al. Venous cutdown versus the Seldinger technique for placement of totally implantable venous access ports. Cochrane Database Syst Rev 2016;2016:CD008942.
14 Lee JE, Kim MJ, Kwak KH. Posterior wall penetration of the internal jugular vein during central venous catheter insertion using real-time ultrasound: Two case reports. Medicine (Baltimore) 2020;99:e22122.
15 Matias F, Semedo E, Carreira C, et al. [Ultrasound-guided central venous catheterization – "syringe-free" approach]. Rev Bras Anestesiol 2017;67:314–7.
16 Takeshita J, Tachibana K, Nakajima Y, et al. Long-axis in-plane approach versus short-axis out-of-plane approach for ultrasound-guided central venous catheterization in pediatric patients: A randomized controlled trial. Pediatr Crit Care Med 2020;21:e996–e1001.
17 Balaban O, Turgut M, Aydın T. Ultrasound-guided supraclavicular brachiocephalic vein catheterization in children: Syringe-free in-plane technique with micro-convex probe. J Vasc Access 2020;21:241–5.
18 Bodenham Chair A, Babu S, Bennett J, et al. Association of Anaesthetists of Great Britain and Ireland: Safe vascular access 2016. Anaesthesia 2016;71:573–85.
19 Saul T, Doctor M, Kaban NL, et al. The ultrasound-only central venous catheter placement and confirmation procedure. J Ultrasound Med 2015;34:1301–6.
20 Lamperti M, Biasucci DG, Disma N, et al. European Society of Anaesthesiology guidelines on peri-operative use of ultrasound-guided for vascular access (PERSEUS vascular access). Eur J Anaesthesiol 2020;37:344–76.
21 Vogel JA, Haukoos JS, Erickson CL, et al. Is long-axis view superior to short-axis view in ultrasound-guided central venous catheterization? Crit Care Med 2015;43:832–9.
22 Takeshita J, Nishiyama K, Fukumoto A, et al. Comparing combined short-axis and long-axis ultrasound-guided central venous catheterization with conventional short-axis out-of-plane approaches. J Cardiothorac Vasc Anesth 2019;33:1029–34.
23 Leidel BA, Kirchhoff C, Bogner V, et al. Comparison of intraosseous versus central venous vascular access in adults under resuscitation in the emergency department with inaccessible peripheral veins. Resuscitation 2012;83:40–5.
24 Ince I, Arı MA, Sulak MM, et al. [Comparison of transverse short-axis classic and oblique long-axis "syringe-free" approaches for internal jugular venous catheterization under ultrasound guidance]. Rev Bras Anestesiol 2018;68:260–5.